All truth passes through three stages.
First, it is ridiculed.
Second, it is violently opposed.
Third, it is accepted as being self-evident.

Arthur Schopenhauer

All pictures by the author except otherwise noted

This book is available free of charge as .pdf file:
www.wildhorse.at/Hoofdeformation.pdf

First Edition, November 2017

Printed in Austria

Dipl.-Ing. Sonja Appelt

Hoof Deformation Revealed

Causes – Consequences - Remedies

A short guide to hoof deformation
for riders, horse owners, veterinarians,
trainers, grooms, horse physio therapists
and other horse professionals.

I'd like to thank
Bruce Springsteen, Patti Scialfa
and the E-Street Band

Your music is keeping me excellent company
during long drives back home at night.

Contents

Preface

Hoof deformation is not a problem of neglect or lack of money. Quite the contrary, it is even frequently found in expensive sports horses that are otherwise extremely well cared for.

The knowledge about hoof deformation and what is causing it is not something new, it is also no rocket science. Focus of traditional farriery is the application of the shoe at the right position under the horse under observation of biomechanics and correction of conformation. Sounds good - but the flexibility of the hoof capsule itself and load distribution on the hoof structures are often disregarded. Daily routine lets us take one shoe off, rasp the hoof flat like a block of wood and fix the new shoe.

Healthy hoof, 310-290 B.C., Louvre de Paris

We continue doing just like we always did, so deformation progresses unnoticed.

The owner does not recognize it, he trusts us as long as the hoof looks nice without chipping, there is a shiny new shoe, grease on the hoof and the horse is not visibly lame.

Horses do not complain and cry out loud, at least not obviously, that is their big problem. As prey animals they are masters in hiding and disguising discomfort. They just change gait a little bit, behave like grumpy bitches, do not build muscles in certain areas despite sophisticated training methods and expensive supplements or appear to be clumsy because reflexes depend on a properly functioning hoof that provides nerve signals.

With time, the slightly changed gait - that also goes unnoticed - can lead to arthrosis, navicular syndrome and other damage as well as premature retirement in sport horses.

Throughout the centuries – at least since the invention of the horse shoe in the Early Middle Ages - horses have had deformed hooves. Napoleon‘s horse had very con-tracted hooves shown in paintings and obviously still did its duty. Even veterinary books show deformed hooves as normal. Many successful jumpers and dressage horses have awful hooves and still perform – at least for a while. So why should we change something?



Carriage Horses with obvious hoof deformation and pain stance. unnoticed by passing tourists. Rome 2016 but unfortunately a very common sight in Vienna, Florence and even New York

Hooves are not just the way they are, they can improve. Today we'd have lots of technical possibilities for hoof protection and correction, once the problem and its cause is recognized and the owner willing to change things. The horses immediately show the relief by licking and yawning, and will probably perform even better.

The intention of this little picture book is to show horse owners, vets and also other professionals what to look for in a hoof without having to read thick anatomy books for hours and hours. Then you don't see the wood for the trees anyway.

Please do not immediately fire your farrier because you have discovered some kind of deformation. Instead you should work closely together to understand the cause and find a way to improve the situation.

Definition of Hoof Deformation

- Hoof capsule is not a solid block of horn but a horn shell with a wall thickness of only ~10 mm
- Front half of hoof is relatively stable as long as the hoof walls are „connected“ to the coffin bone by a healthy laminar corium. Then the wall at the toe is growing down straight like on rails.
- Hind half of the hoof capsule can bend, twist and widen as it acts as dampener and was made to compensate rough terrain. There is flexible cartilage and connective tissue inside
- Deformation develops when parts are overloaded, restricted in expansion or forced to grow into the wrong direction
- Contraction means a part of the hoof capsule is too narrow and pinching the sensitive corium. Probably feels like a pinching or rubbing shoe or a stone inside, at least not comfortable.

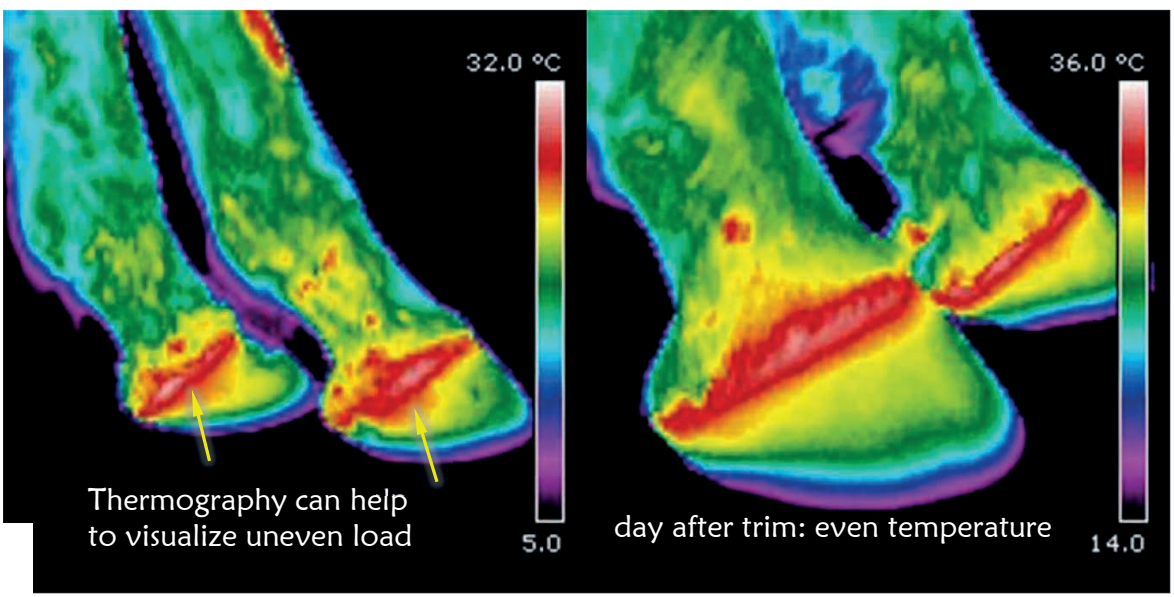

Pain Stance (see picture page 7)

- Regular stance: all cannon bones vertical, fetlock axis straight
  -> even load distribution onto the hoof capsule
- Heel pain in fronts -> horse shifts weight to toe
  -> front cannon bones behind vertical (1)
  -> higher muscle tension in shoulder (5)
  -> often steeper fetlock than hoof (broken axis) (2)
  -> often hind hooves will be placed too far forward in order to relieve fronts (3)
  -> muscles in hinds and croup (6) cannot work properly, often leading to a dent in the croup
- Sole/toe pain -> hoof is placed forward
- Pain in hind hooves:
  hoof lifted forward (4) - this is not the normal relaxed position. Sole would point backwards positioned under the leg

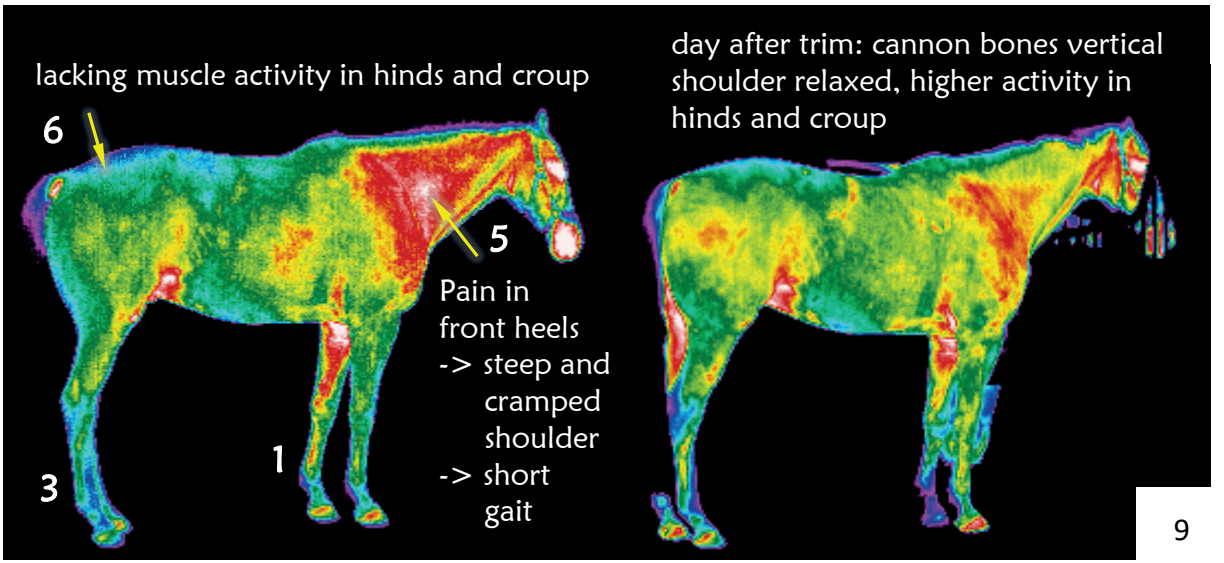

Basic anatomy – structural elements

- Coffin bone transmits the horses weight from pastern bones to hoof capsule. Specially shaped for that purpose, is no marrow bone but supplied by blood vessels -> exit through holes in dorsal surface

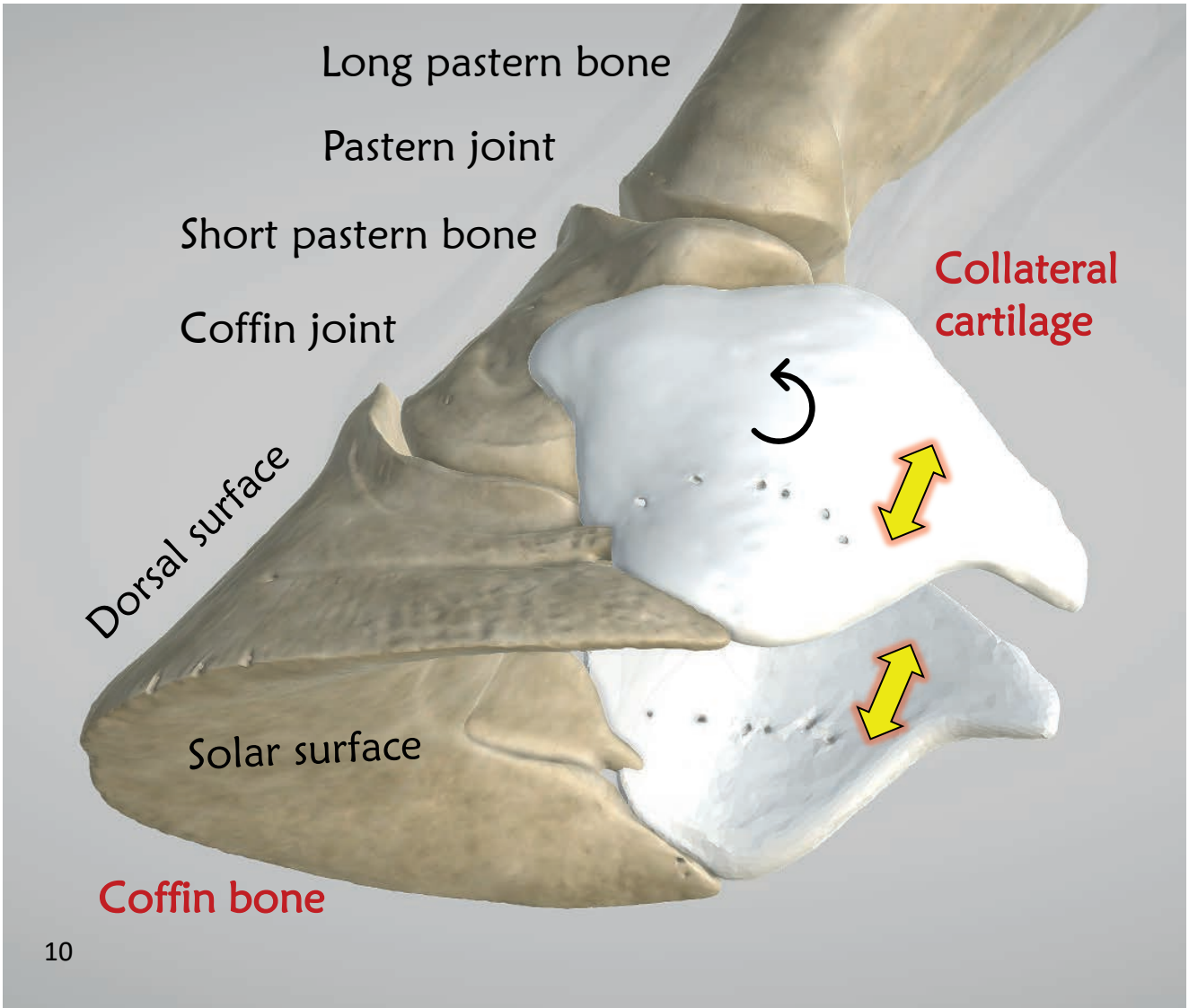

- The dome shaped solar surface of the coffin bone is **not** designed to carry the horses weight but supports it. Main load is transferred from hoof wall to dorsal surface via a healthy laminar corium

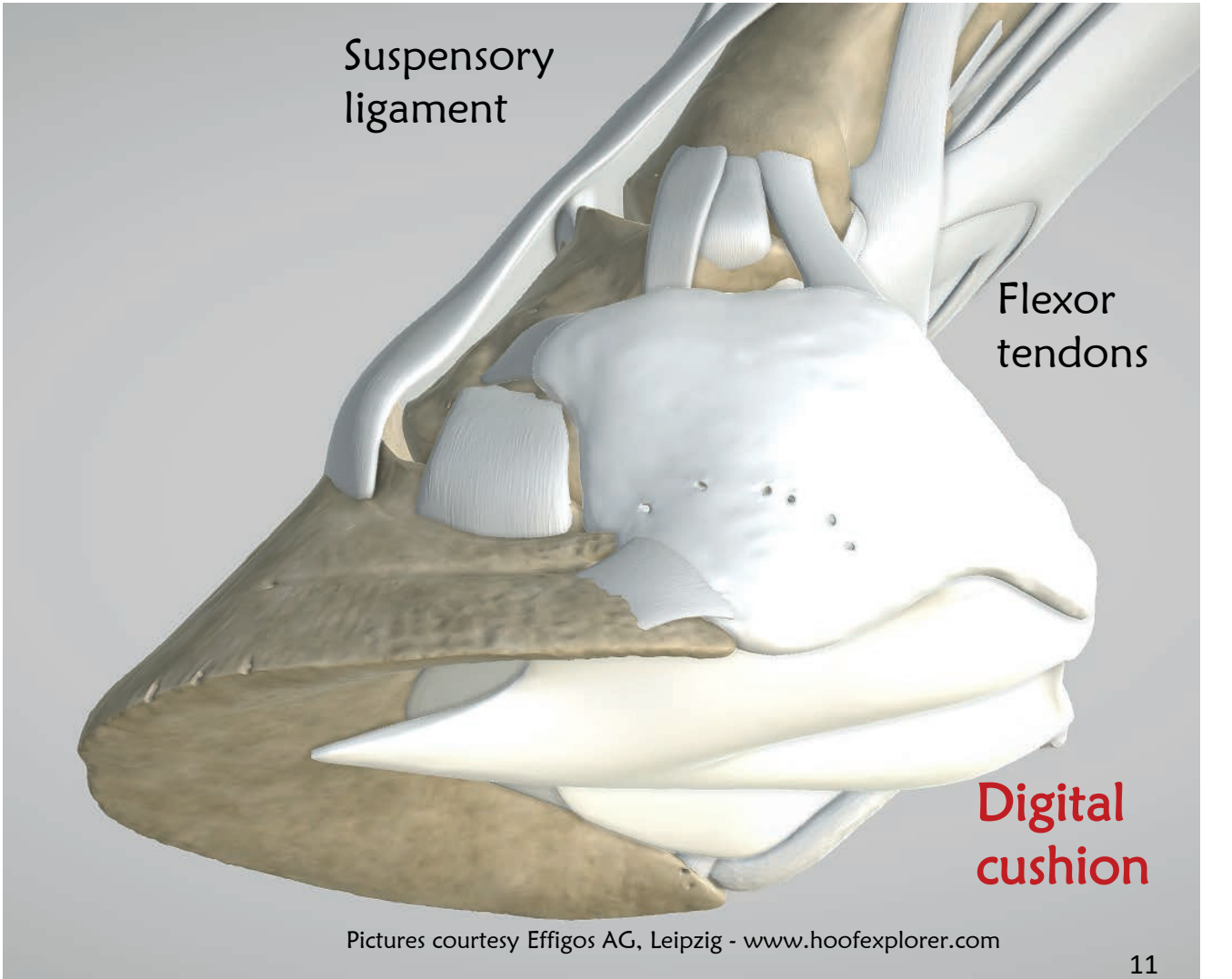

Pictures courtesy Effigos AG, Leipzig - www.hoofexplorer.com

Basic anatomy – structural elements

- Collateral cartilage shapes hind half of hoof
  -> allows for torsion of the hoof capsule (uneven ground)
  -> dampens impact when horse lands on heels
  -> strength depends on stimulation (movement, torsion)

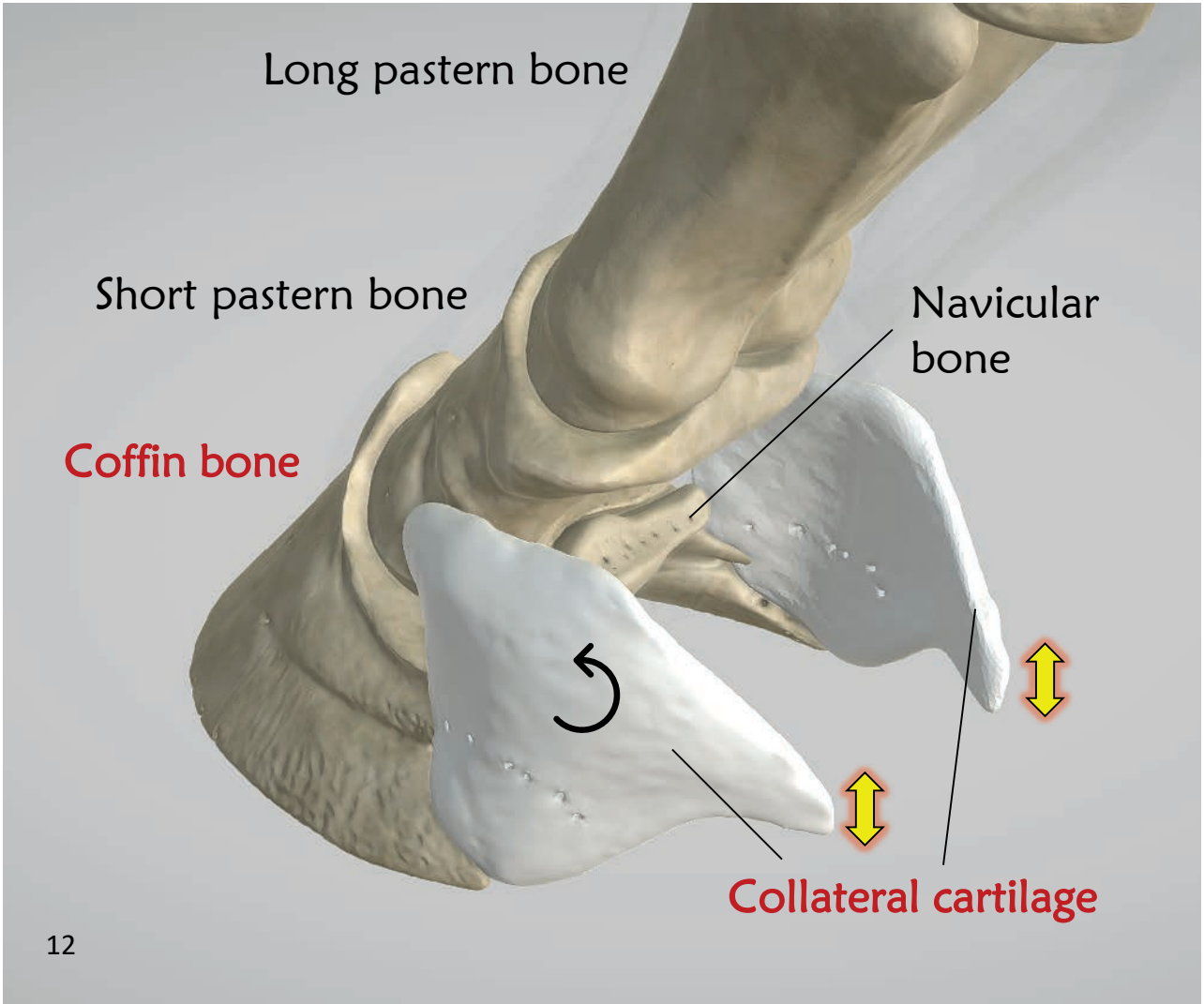

- **Digital cushion** is a mass of connective tissue above frog
  -> expands heels upon pressure on frog
  -> cushions deep flexor tendon and navicular
  -> strength depends on stimulation (movement, load)

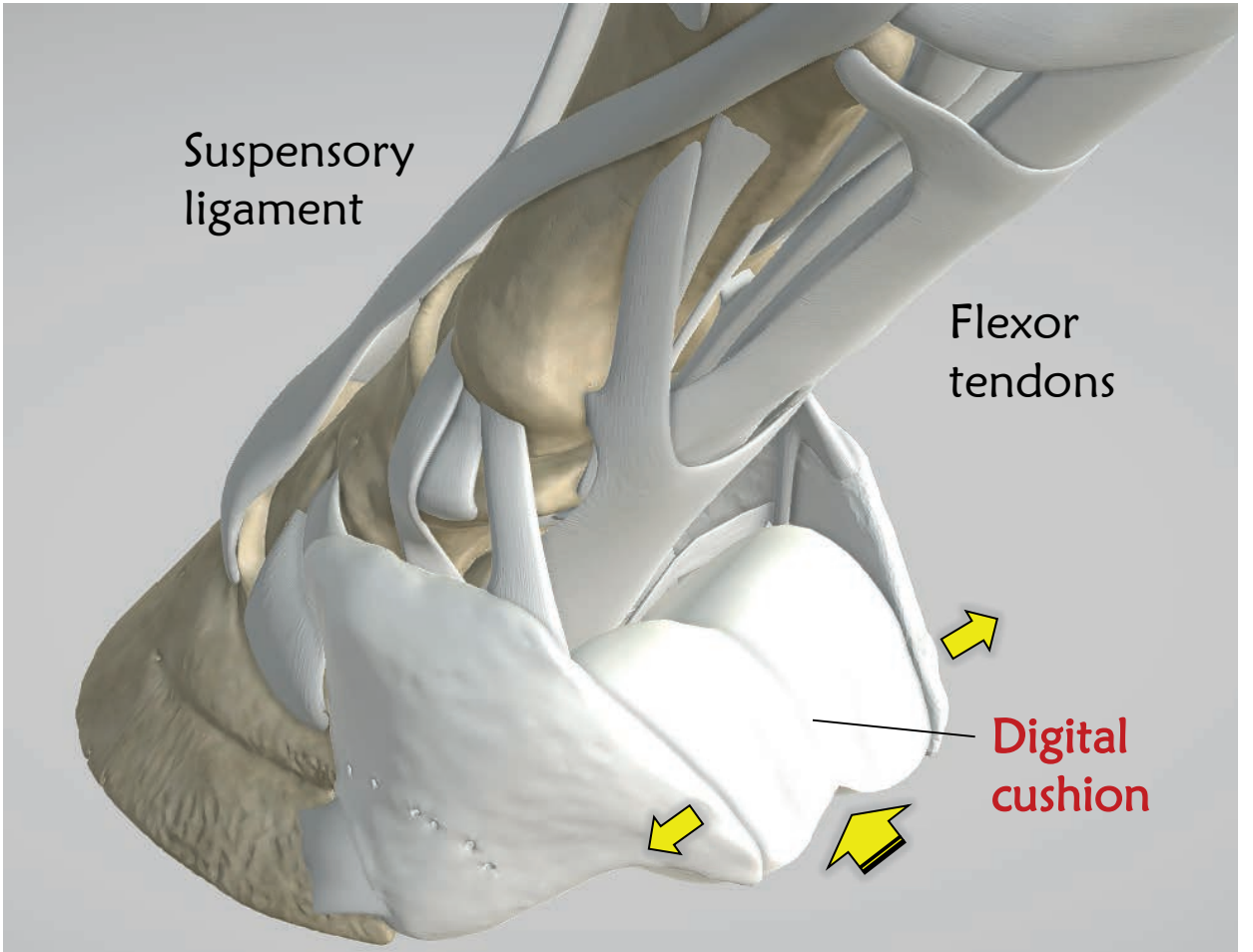

Pictures courtesy Effigos AG, Leipzig - www.hoofexplorer.com

Basic anatomy – corium and hoof capsule

- structural elements are surrounded by ~ 3 mm thick sensitive corium equal to nail bed in humans. -> horse can feel distortions and pressure of the hoof capsule, and tearing forces of long walls

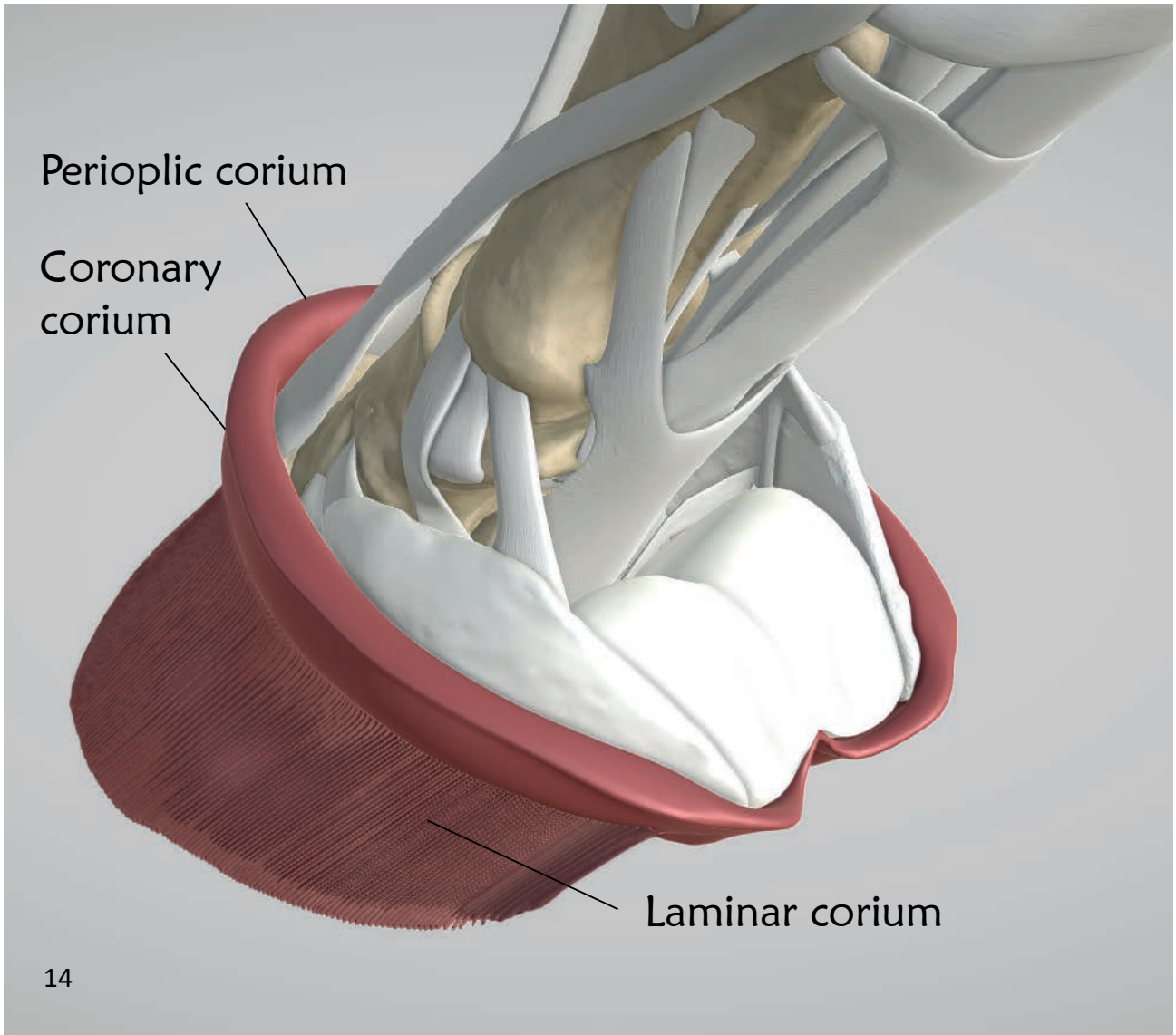

- Corium is very well supplied with blood and nerves.
- Nerve function and horn growth depends on blood supply. Lack of blood due to constant pressure will result in bad horn growth

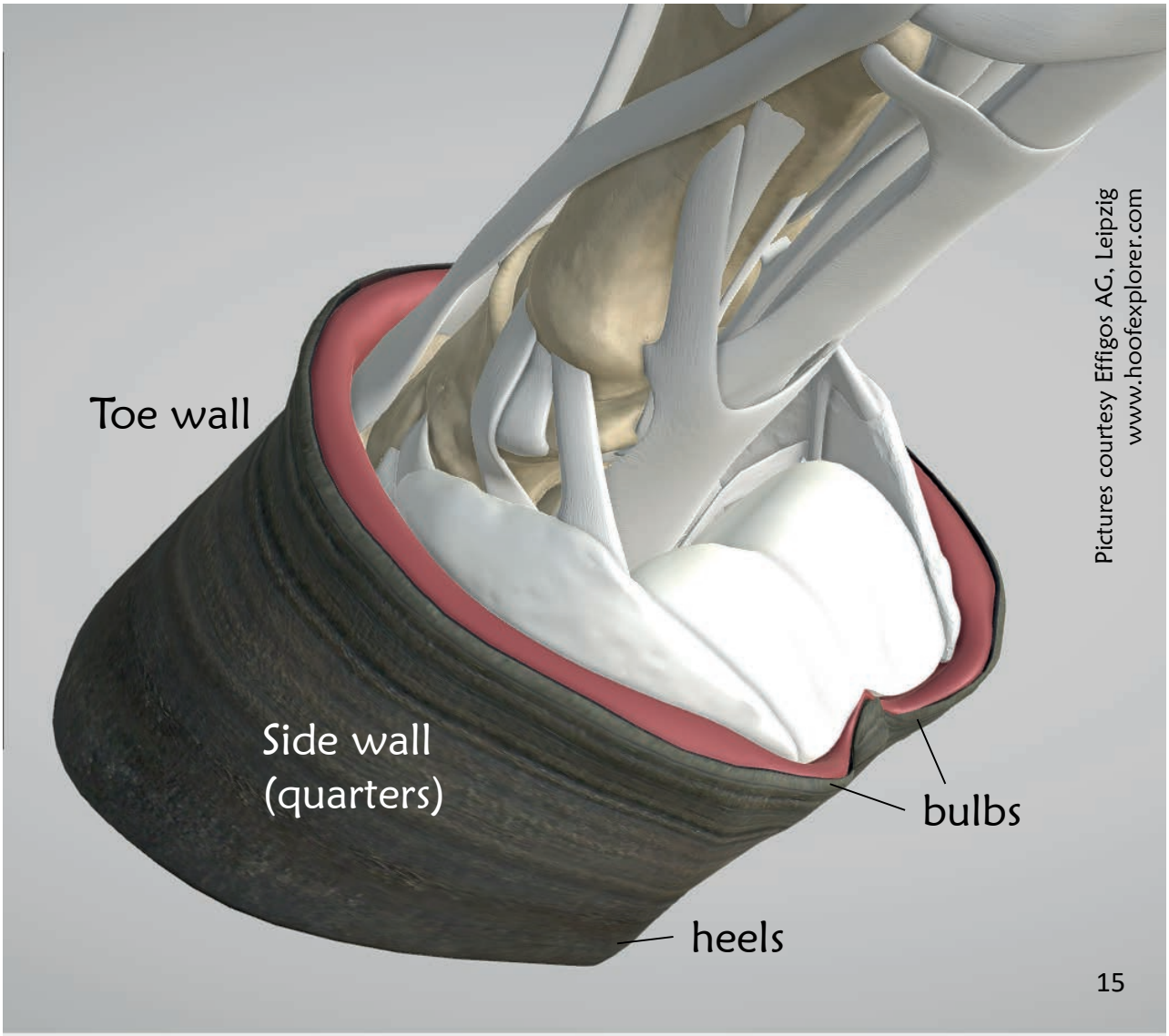

Basic anatomy – corium and hoof capsule

- accordion shaped frog corium -> soft frog horn
- dome shaped solar corium -> sole horn
- coronary corium -> hard horn of hoof wall and bar

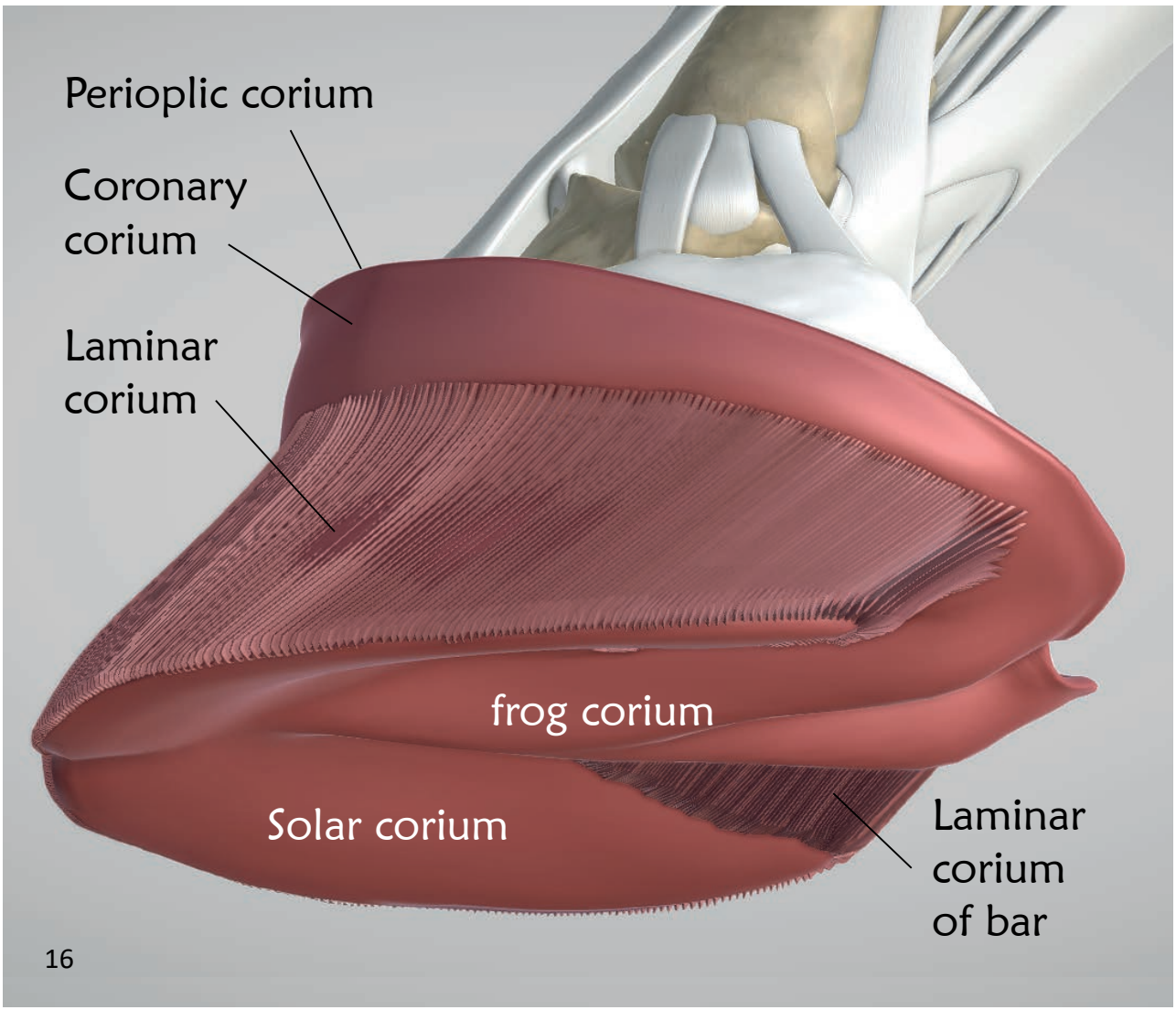

- perioplic corium -> soft horn layer covering the coronet
- laminar corium attaches wall to coffin bone in front half and lateral cartilage in hind half, **bears the horse's weight!**

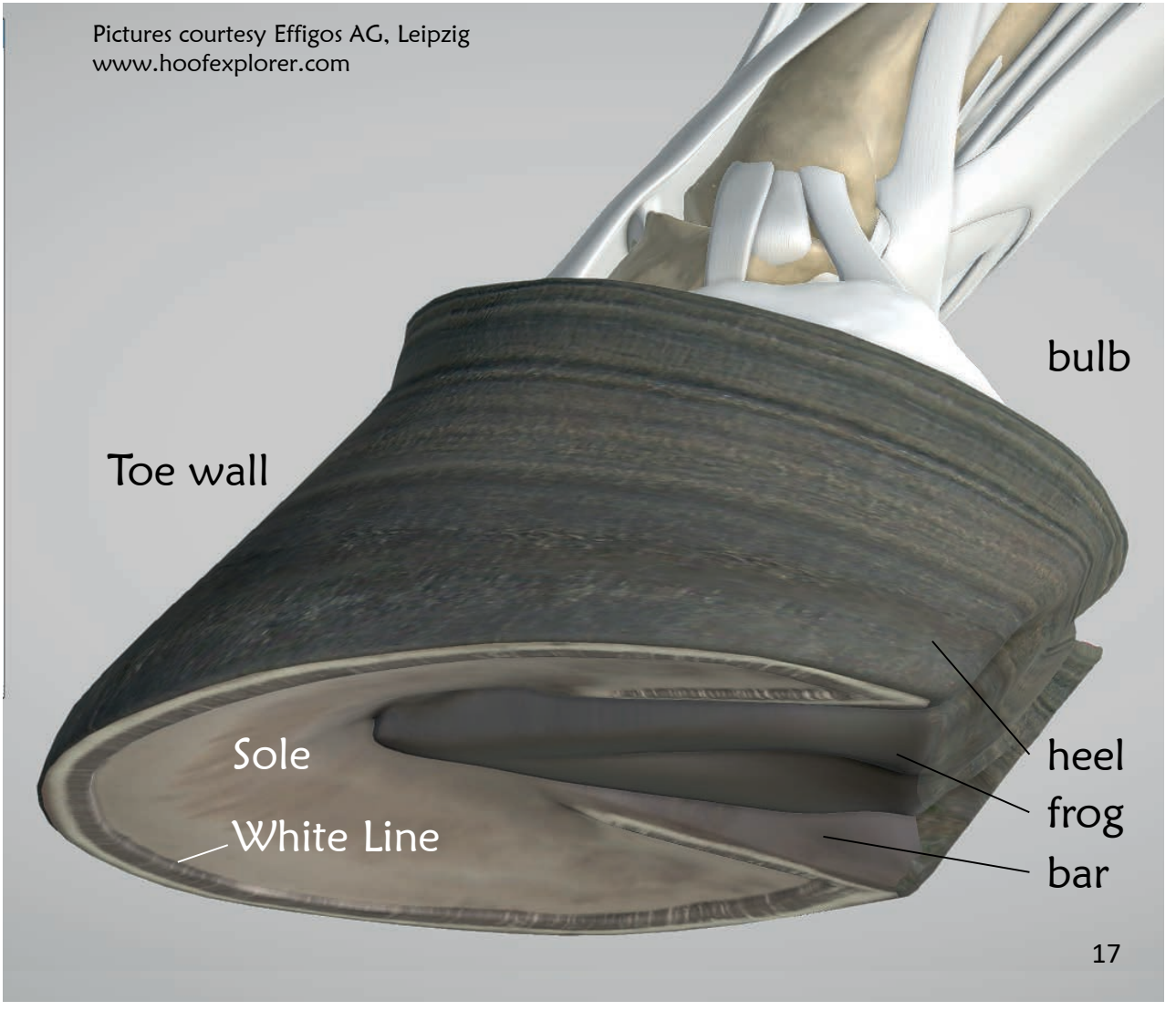

Hoof mechanisms

- Traditional view: hoof mechanism = widening at heels (1)
  -> last nail should be before tip of frog so that hoof mechanism can work, that means the heels can slip outward on shoe
- But: hoof capsule is flexible in more aspects as a reaction to load and ground conditions -> more hoof mechanisms
- When hoof mechanisms are restricted -> deformation results
- Good news: Hoof capsule is elastic and grows down. When restriction ist removed, it will tend to return to normal shape pretty quickly (relax) or grow out deformations.

1. Horizontal expansion at heels about 2 mm
2. Horizontal expansion at bulbs should be equal to that of heels. Important: This works only with actively weightbearing frog Please watch Youtube: „Hoof Proof 2“ by Swedish Hoof School
3. Torsion of heels and bulbs to compensate uneven ground up to about 1 cm

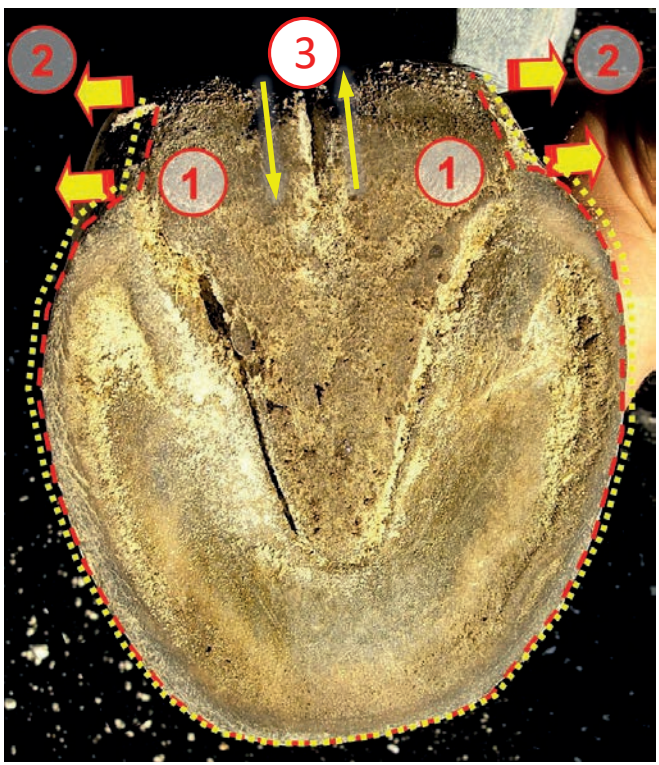

4. Flattening of toe angle
5. Slight sinking of side walls (quarters)
6. Slight expansion in length at ground level
7. Flattening of vaulted bar (arch of bar)
8. Flattening of vaulted sole (arch or concavity of sole) in longitudinal and lateral direction
9. Local shear of tubules to compensate for rocks



Load Distribution in the wild…

- There are no paved roads in the wilderness
- Soft but abrasive surface distributes load and abrasion evenly on all structures, relatively little load on hoof walls
- Abrasion shapes typical compact mustang hoof with rounded walls (mustang roll), shorter side walls (scooping) and toes

Front Hoof print on typical wild horse range terrain in the Pryor Mountain Wild Horse Range, Wyoming
Main load on frog and sole, little load on wall, uniform abrasion on whole surface

and on compacted ground

Wild Horse

- Compacted ground -> less sole support
- More load and abrasion on hoof wall and frog, less on sole and bars. Abrasion on wall is also different, less on side wall
- Shoes lift hoof off ground, giving less frog support. Load almost entirely on hoof walls. Abrasion completely eliminated.

Hoof print
on compacted ground:
healthy frog takes weight,
expanding heels and bulbs,
reducing load on heels and side
walls, but sole is poorly supported

Natural Hoof Shape

- Right hind hoof of a feral stallion, never touched by a farrier!
- Lots of movement and stimulation have built strong lateral cartilage and digital cushion
- Weightbearing frog expands heels and bulbs and in turn grows thick and healthy
- Sole arch can flatten when loaded
  -> old sole exfoliates by itself to uniform thickness
- Abrasion acts evenly on surface, that means zones with harder horn get less abrasion
  -> side walls wear more, are shorter than heels and toe
  -> no overload of side walls, bulging, underrun heels…
- Result is the characteristic hoof shape:
  - straight short and thick walls (as they receive little load)
  - strong frog, wide heels and bulbs
  - tight White Line without stones
  - homogenously vaulted sole that matches shape of coffin bone
  - hoof walls that wear down to slightly above sole
  - straight bars, shorter than walls, slightly above sole
  - heels just a little higher than frog
  - rounded walls („Mustang Roll“)

Hind hoof of a feral stallion, Dry Lake Wild Horse Range, Nevada

Healthy Hoof Shape – Side View

- hairline	–> straight
- toe	–> straight
- heel	–> parallel to or steeper than toe
- horn tubules	–> +/- parallel to toe
- growth lines	–> parallel to hairline
- coronet	–> smooth, no edge
- hoof – fetlock axis	–> straight
- collateral cartilage	–> prononced, full bulb

well developed collateral cartilage in a healthy front hoof



Hoof Angles

1) toe-ground angle	–>	fronts	52° +/-5°
	–>	hinds	57° +/-5°
2) hairline-ground angle	–>		23° +/- 5°
3) hairline-toe angle	–>	fronts	~ 105°
	–>	hinds	~ 95°

Deformations – right hind

- Wall overload in 18 y. Hannoveran dressage horse, „always shod“

Deformations – left front

- This horse was just deshod and already trimmed to shortest possible toe. Doesn't look that bad at first glance but:

1. Toe is still high despite trimming, indicating -> sole contraction
2. low lateral cartilage in respect to coronet -> heels pushed up
3. sharp bend in hairline -> rotated collateral cartilage

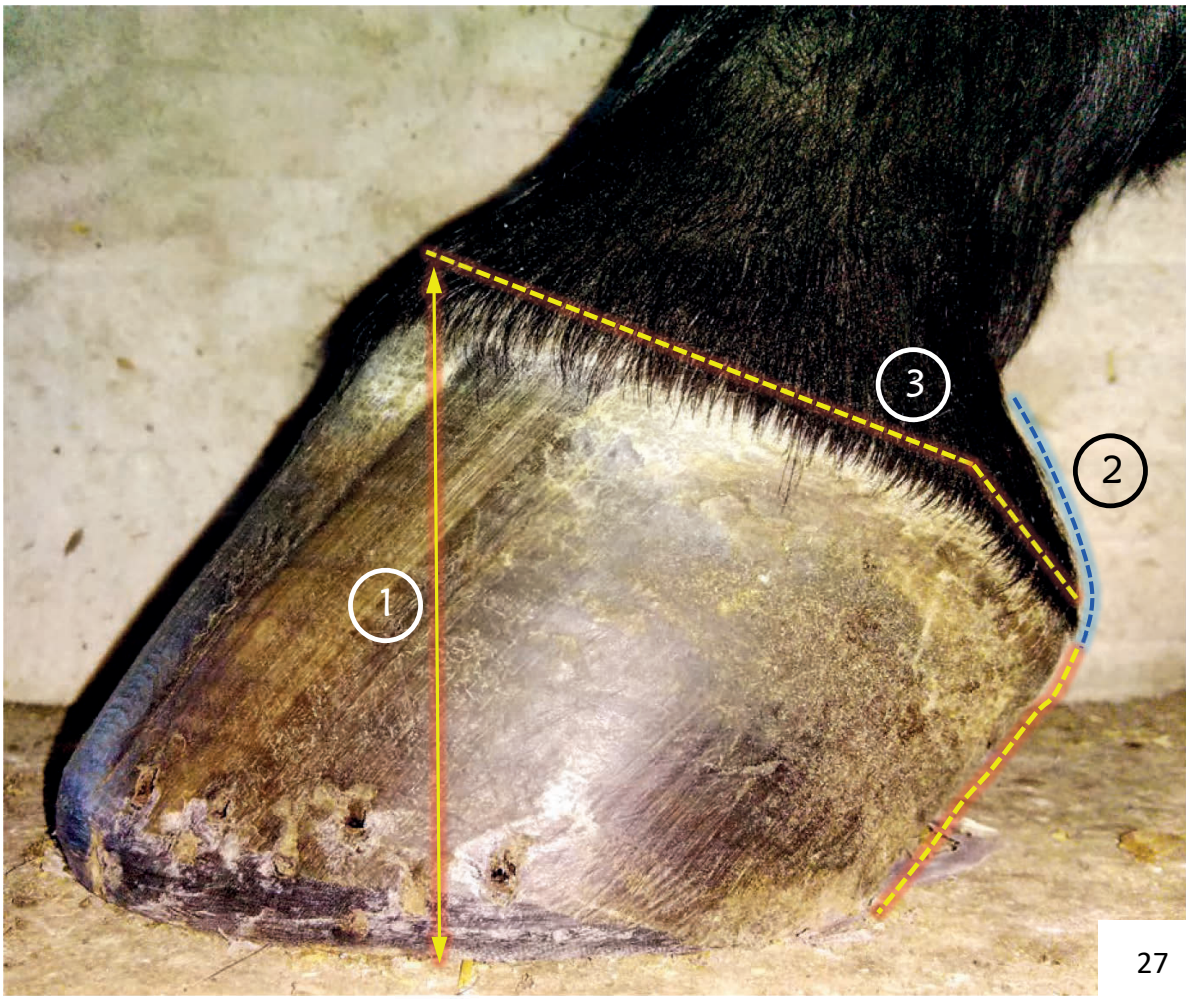

Heel to Toe Relation

- Center of rotation (coffin joint):
  coronet length -10%, then 1/3rd from the front
- Front (A) and back (B) of hoof should be equal length
- Short toes are key to healthy tendons and navicular area




Icelandic Pony of page 52, left front
Goal for correct balance: B=A
30%
Center of rotation
-10%
A
B

Healthy Hoof Shape – Bottom view

- smooth sole arch corresponding to arch of coffin bone not too steep and not too flat, no inflammation signs
- straight bars, ending about center of frog

- healthy white line, +/- 3 mm wide
- outer circumference symmetric to rim of sole
- hoof about symmetric to center line of frog
- hinds typically a little wider on lateral side



Healthy Hoof Shape – Hind View

- Pronounced collateral cartilage above hairline
- Follow heels up to hairline -> bulb width
- Relaxed central sulcus in hairline
- Bulb Height (lowest points of hairline!) ~ 30-40 mm
- Heel height (heel origin in hairline) ~ bulb height
- Angle of side walls and heels to ground >90°
- Heels slightly slanted inward ~ 5-10°

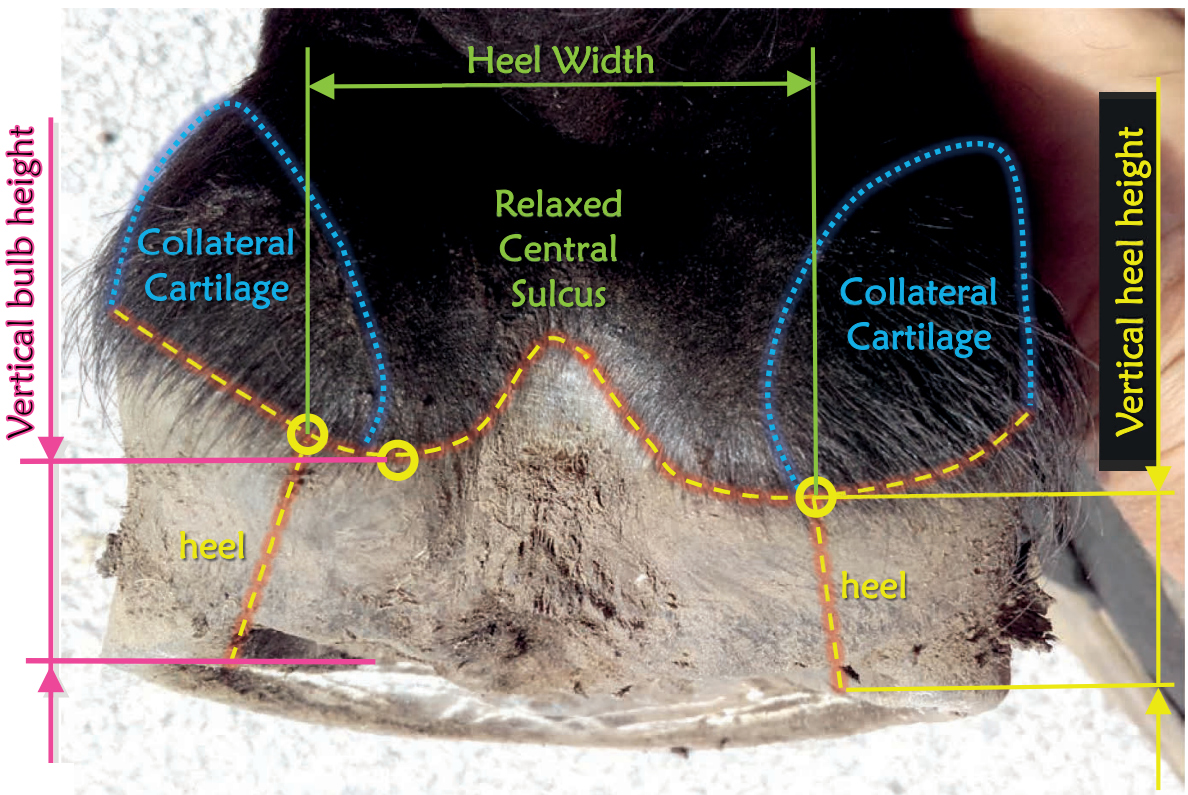

Problems…

- Pinched central sulcus and collateral cartilage
  -> bulb contraction
- Heel >> bulb height -> Heels pushed up, seem long
  -> collateral cartilage deep down inside heels
- Right side wall and heel <90° -> heel contraction

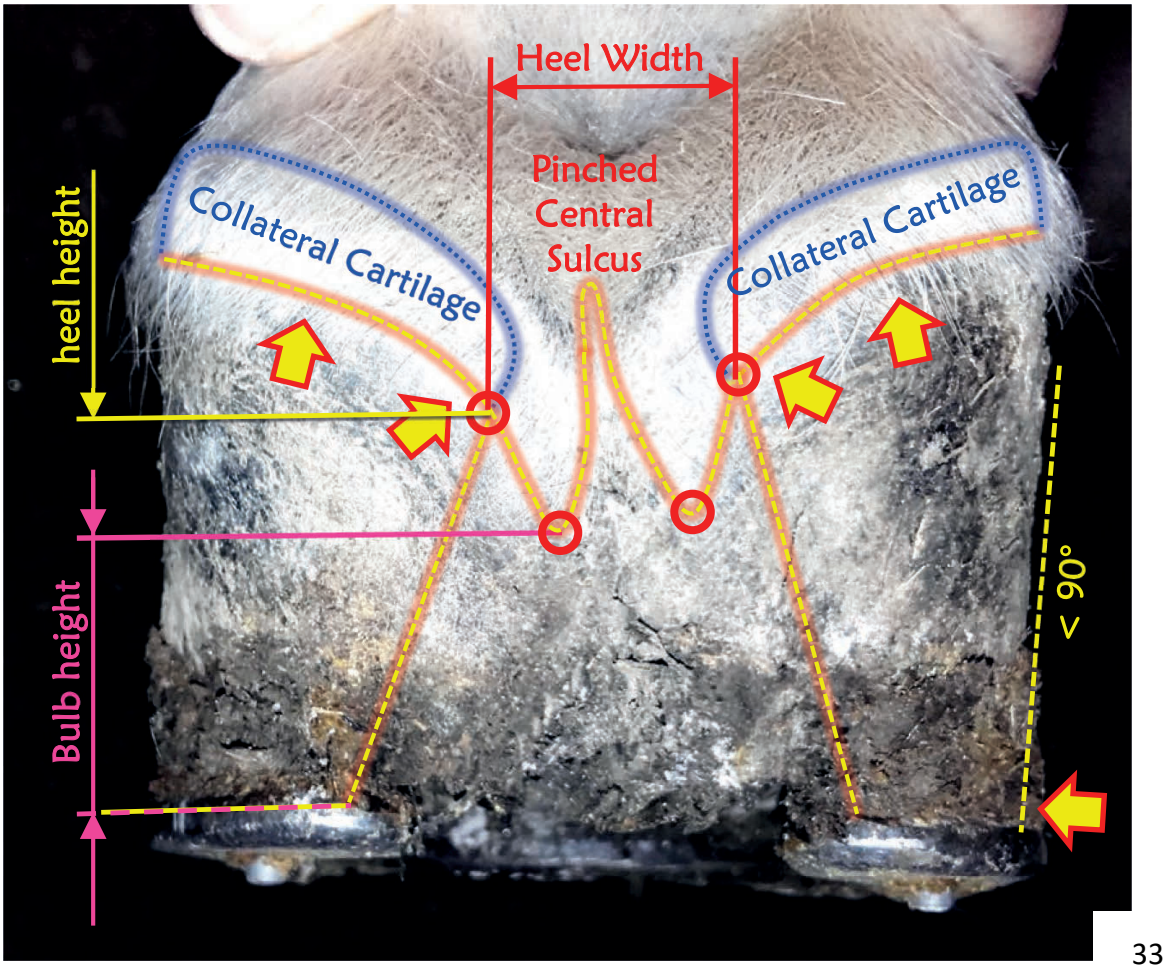

Healthy Hoof Shape – Front view

- center line perpendicular to ground
- one wall may be a little steeper, but not steeper than vertical
- straight side walls without dishing
- slightly flatter outer wall is normal in hind hooves
- Too long, bending or thickened walls cause tearing and pain in laminar corium -> horse shifts load to opposite side
- once lever is removed, horse immediately licks and chews as a sign of relief

Healthy Hoof Shape – Top view

- Shape of wall at ground level should follow coronet
- Hind hooves have rather triangular shape, fronts round
- Hoof should be symmetric „under the horse“
- Follow coronet and growth lines to correct long walls
- Less loaded walls will have less abrasion and grow long
- Conformation errors („crooked legs“) can often not be fully corrected but the resulting deformation on the hoof must be adressed, otherwise the horse shifts load to opposite side and the conformation error becomes worse

Signs of Stress on the Hoof

1. Bloody white line is not always „bruising“ due to hits from outside but from tearing forces on laminar corium or direct inflammation (laminitis). Frequently seen with long toes like here.
2. Bloody dots/lines on outside of white hooves: wall is tearing the laminar corium, also no bruise!
3. Pigmentation of skin is switched by stress (pressure) -> horn produced there will have different color The pigmentation switch is semipermanent, it can fade with time. Here the frog was pinched by bars
4. Poor horn growth due to permanent pressure – here the frog could not grow because of bar pressure that pinched the blood supply
5. Yellow horn on sole due to inflammation (inclusion of inflammation fluid). With organic problems hooves can even turn completely yellow on the outside wall
6. Wall overload in heels and side walls -> thin walls High pressure of the wall into coronet (e.g. by shoes) causes horn with bad quality, slow growth and thinner wall. When pressure is relieved, thick wall starts growing down with 1 cm/month.

„This horse simply has bad hooves“ is mostly not true, they have been made bad, but things can be changed.

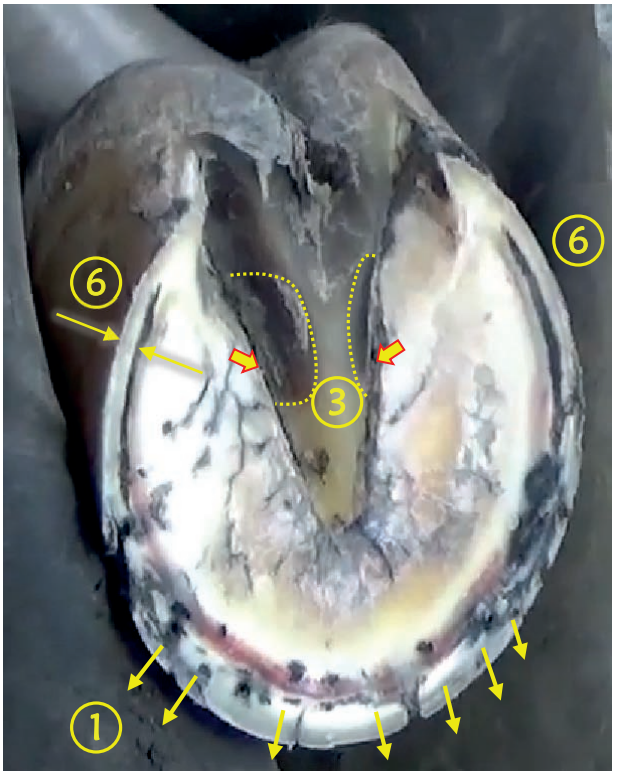
6
6
3
1

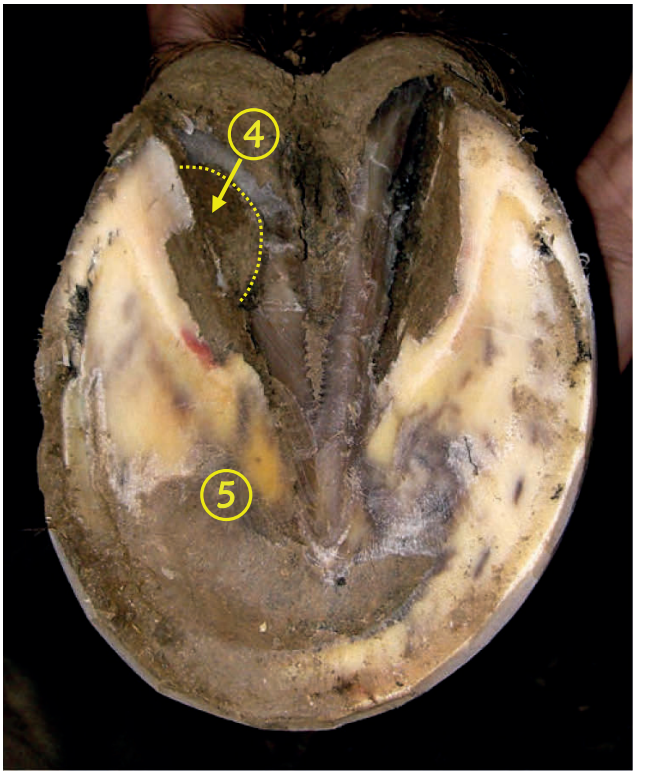
4
5

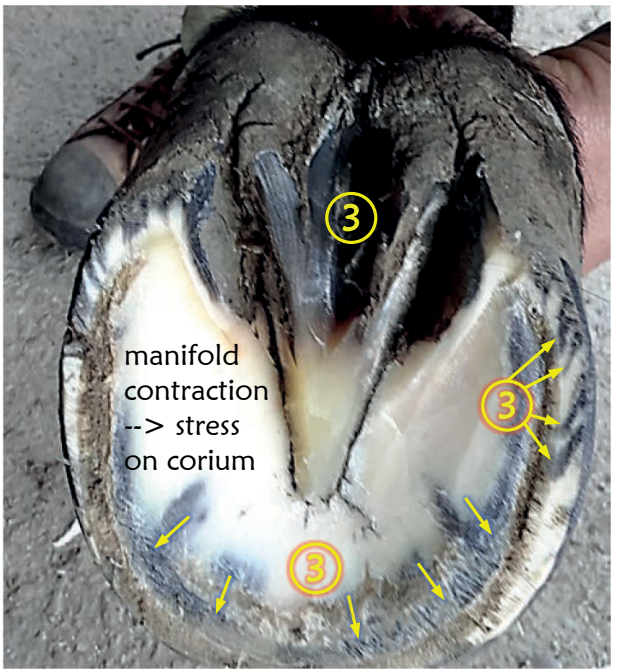
3
manifold
contraction
--> stress
on corium
3
3


2

Bulb Contraction

- Very frequent deformation and seldom adressed
- often regarded as normal like in this „Handbook of animal anatomy for artists“ of 1901
- Can only be evaluated in view from behind
- front, side and bottom view of the hoof look normal
- follow the heels up to their origin at the hairline
- Collateral cartilage is bent inwards
- Central frog sulcus is pinched -> tend to develop thrush
- Reason is lack of pressure on frog e.g. with regular shoeing, hard ground conditions or already bad frog quality
  Frog needs to be firm and thrush free, not mushy, in order to transmit the ground force enough to open the heels
- For reversal:
  - active weightbearing frog
  - Shoeing: Apply suitable frog pads
  - Hoof boots: use EVA pads, fit to frog height
  - Suitable ground conditions (dry and supportive)
  - Optimum: 24h turnout in 1-2“ deep pea gravel

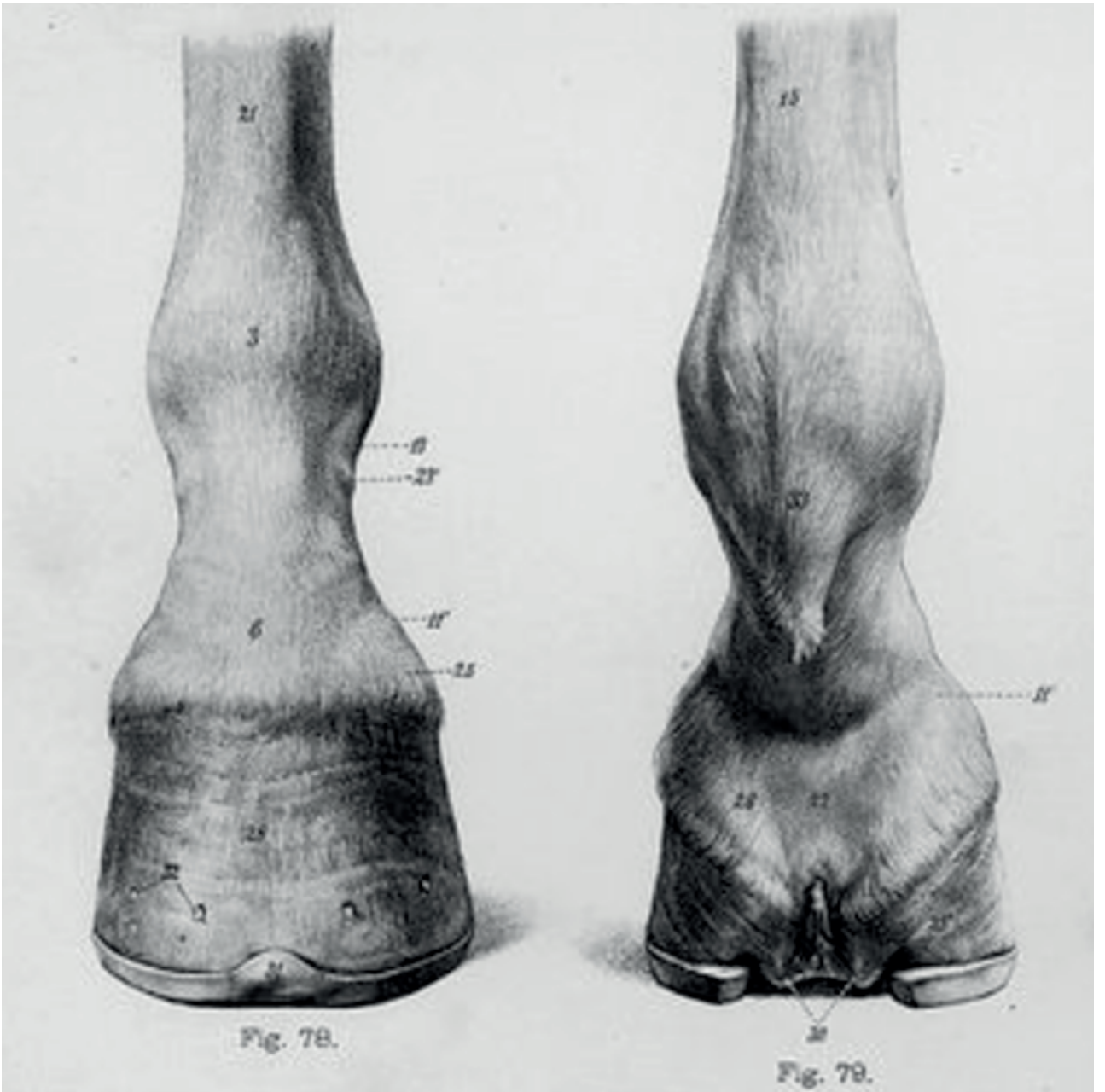

From: „Handbuch der Anatomie der Tiere für Künstler“
Hermann Dittrich, 1901

Reversing Bulb Contraction

- Shift load from heel to frog
- Do not shorten heels below +/- 30 mm bulb height
- Heels look deceptively long as they are pushed up
- This frog is already too thin, do not trim!



Compression rings in side wall due to high pressure

Sharp edge, „empty“ coronet -> heel wall has been pushed up past collateral cartilage.
Heel appears high in lateral view but it isn‘t

- Unload heels and side walls
  -> less pressure at the coronet
  -> faster wall growth and thicker walls
  -> less deformation

Shorter side walls, no compression rings

Rounded, „full“ coronet -> heel wall has returned down to normal position, collateral cartilage visible at coronet

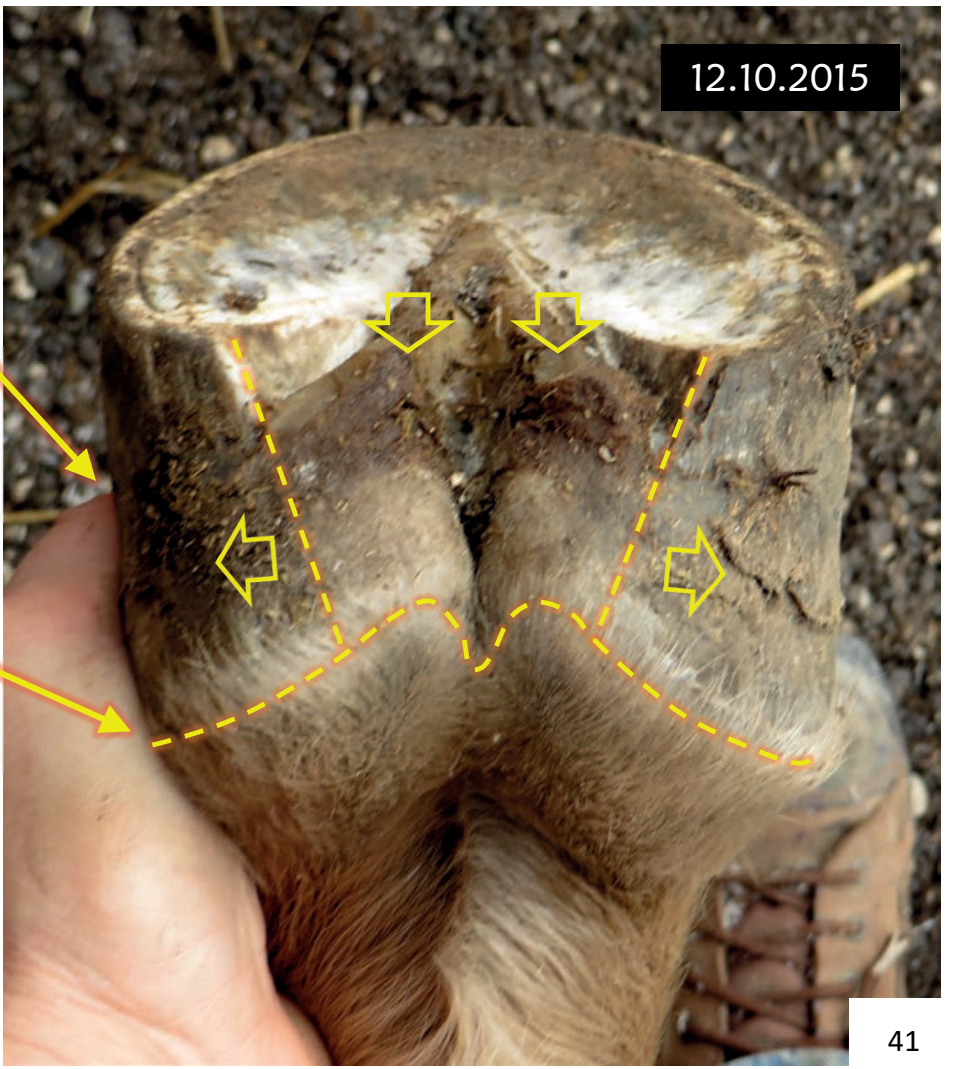

Reversing Bulb Contraction

- 1,5 years after deshoeing and slow progress, finally the frog is strong enough to support and actively widen the bulbs even on compact ground. In this case it took quite some time, small hooves of a relatively lightweight arab, long-time contraction…
- Use every possibility to load the frog for faster progress!

Active frog support for progress

A load of pea gravel for paddock

Rubber frog support in Easy Shoe

Variety of impression materials

Pads for hoof boots
www.easycareinc.com



Flexible frog support under shoes
www.razerhorse.com

Frog support must be flexible
to actively push up the frog!

Bulb Contraction & Thrush


Pinched frog corium
Extreme heel, bulb, bar and sole contraction
Tips of bars are pinching frog
White areas on solar corium: pinched corium, lack of blood, reduced nerve function
thrush

Thrush

- Frequent problem with bulb contraction
- Frog sulcus walls are pinched and cannot produce horn with good quality due to lack of blood

- Perfect conditions for fungus and bacteria:
  humid, warm and lack of oxygen
- Infection undermines the frog starting from the sulcus
- Thrush is painful, horse starts avoiding to load the heels
  -> toe first landing that can even lead to navicular disease

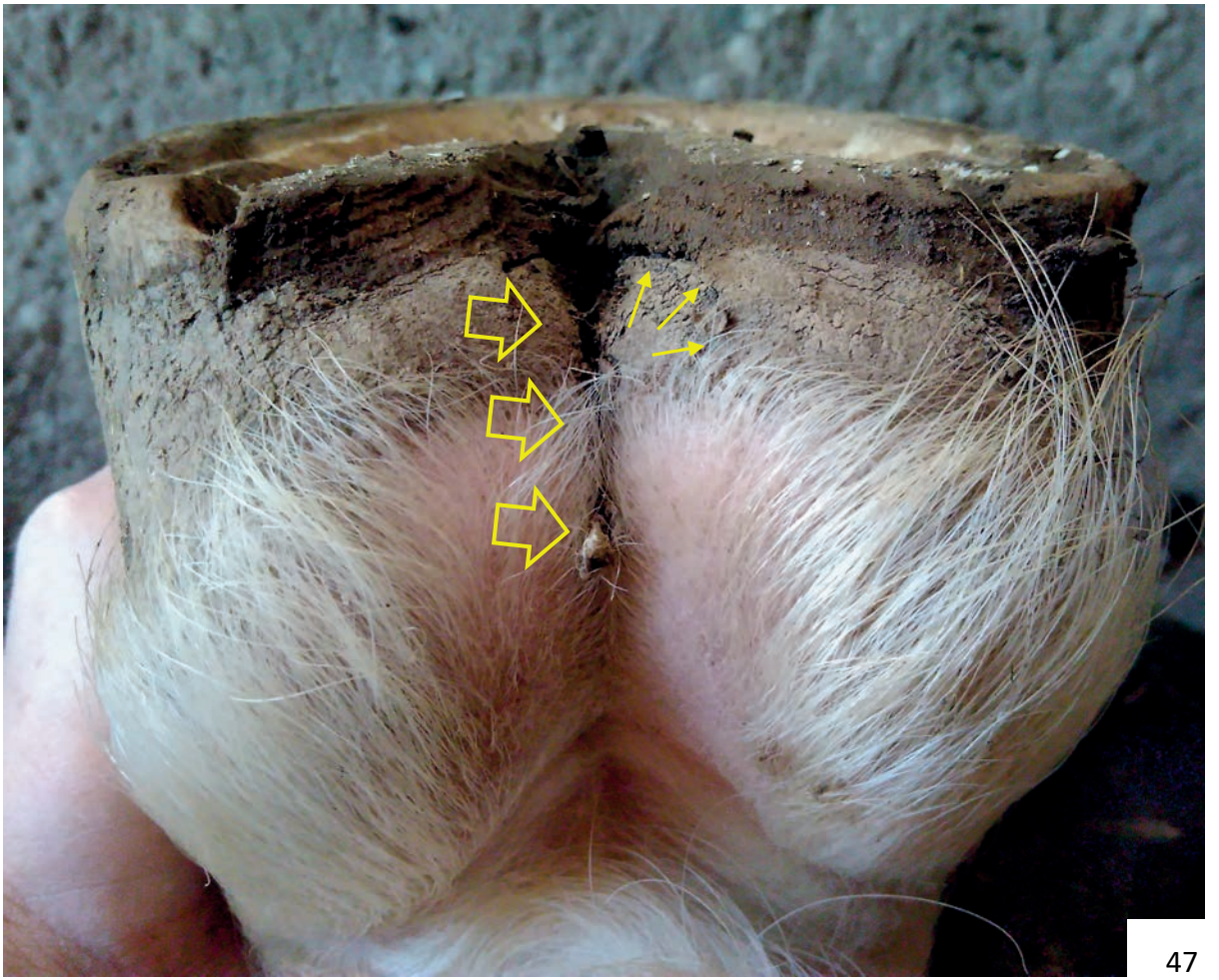

Thrush

- Frog becomes weak and mushy -> no help in decontraction

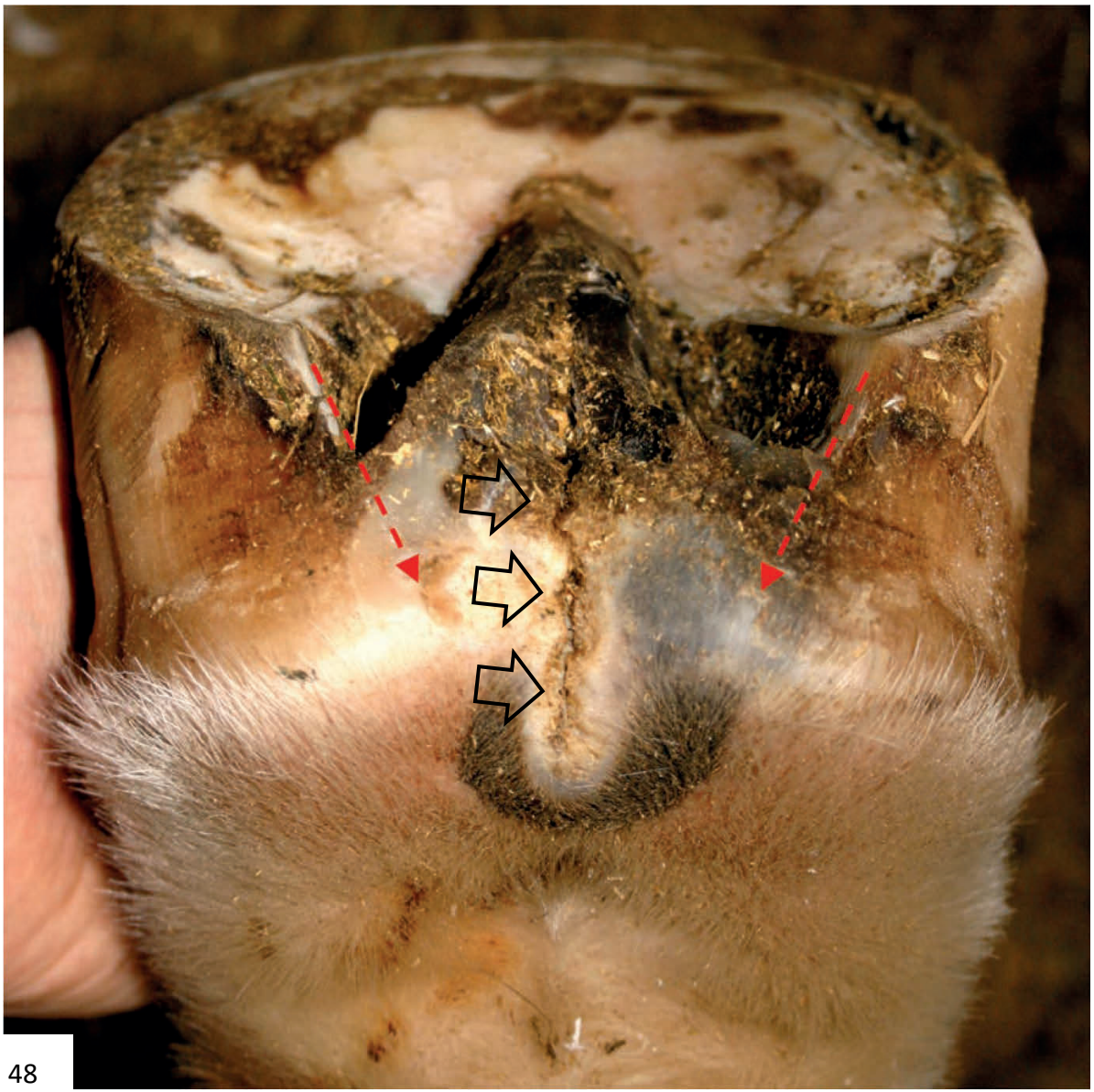

- Infection undermines coronary sideways -> thrush rings

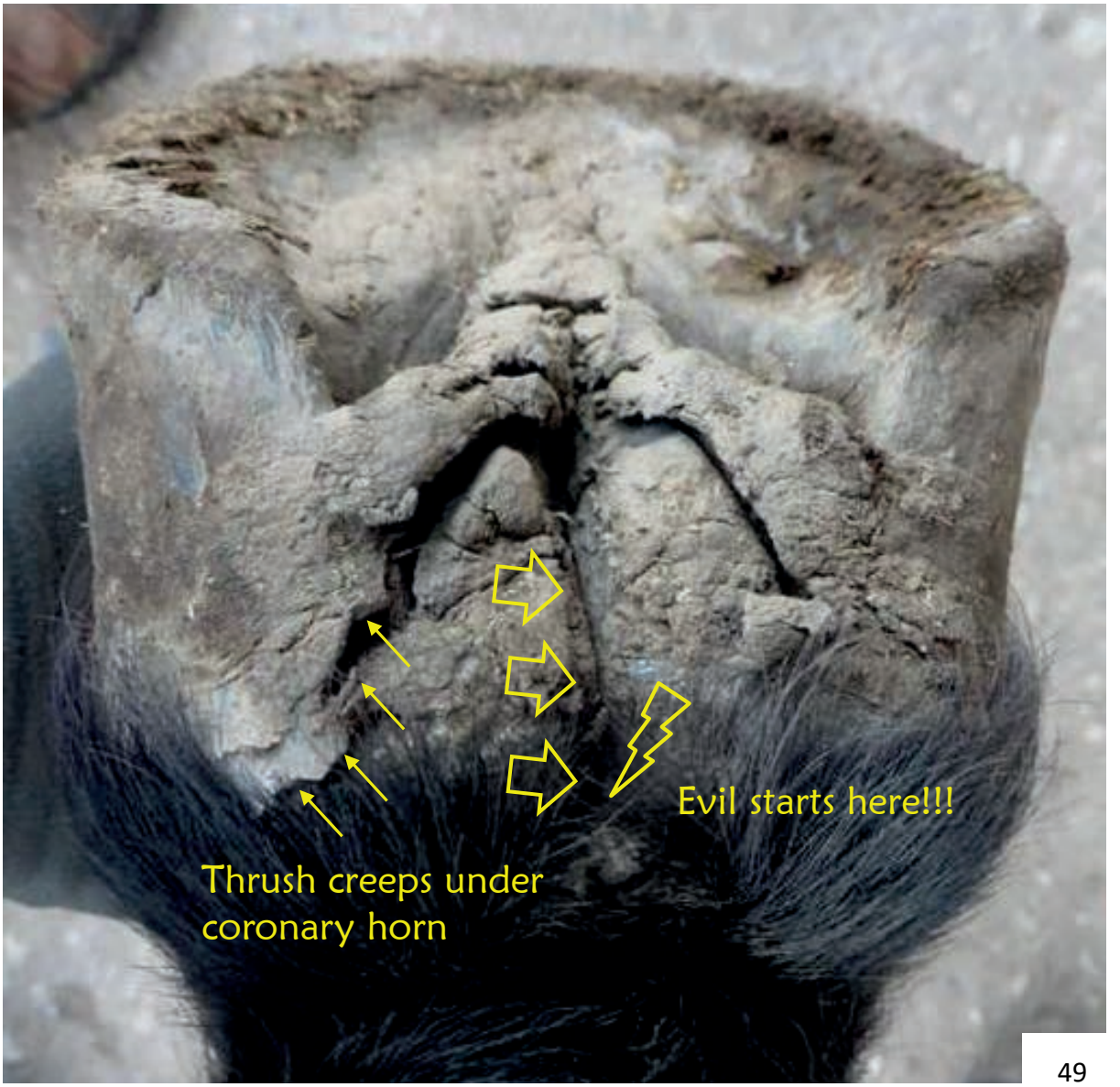

Thrush rings

- from thrush infection that starts creeping under perioplic horn at heels. Periople is a thin soft horn layer that protects the coronet. Sometimes it becomes flaky when undermined by thrush
- Infected local bubble moves invisibly along the coronet
- At the location of the bubble, inflammation is causing thicker wall growth -> visible as „ring“ on hoof wall surface

- Wall is growing down while infection bubble is moving along -> spiral ring of thicker wall around hoof
- Find infection spot where ring runs into coronet
- Scratch open and desinfect with thrush remedy or antifungal
- Don‘t forget to address thrush in central frog sulcus
  And its underlying cause - bulb and/or heel contraction

Thrush -> Frog Canker


09.09.2017

Thrush -> Frog Canker


09.09.2017

Heel Contraction

- Wall horn at heels is pushed forward/inward
- Bar forced forward into the hoof -> bar contraction
- heel pain, horse changes gait, toe first landing -> navicular
- Long flat toes have caused this extreme heel contraction

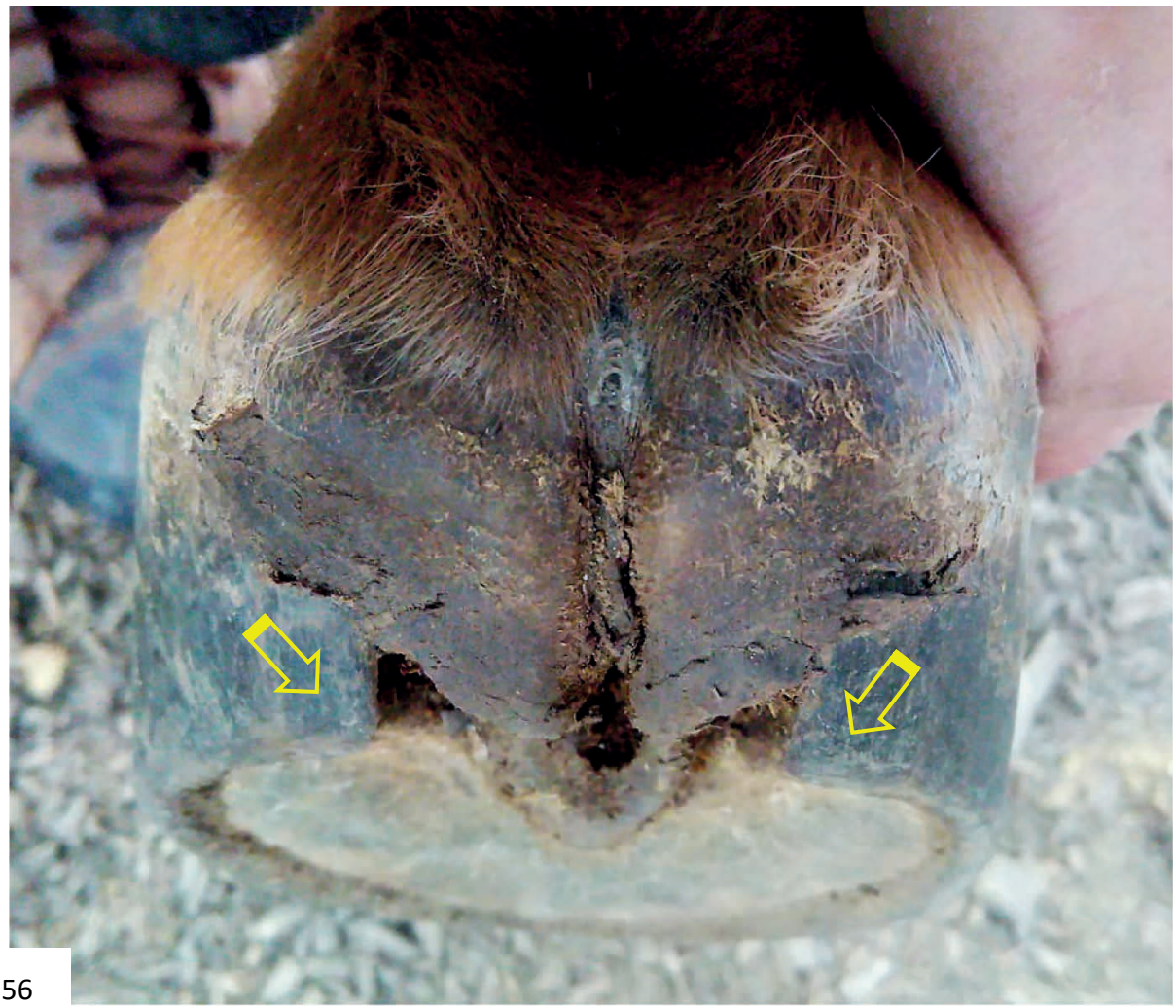

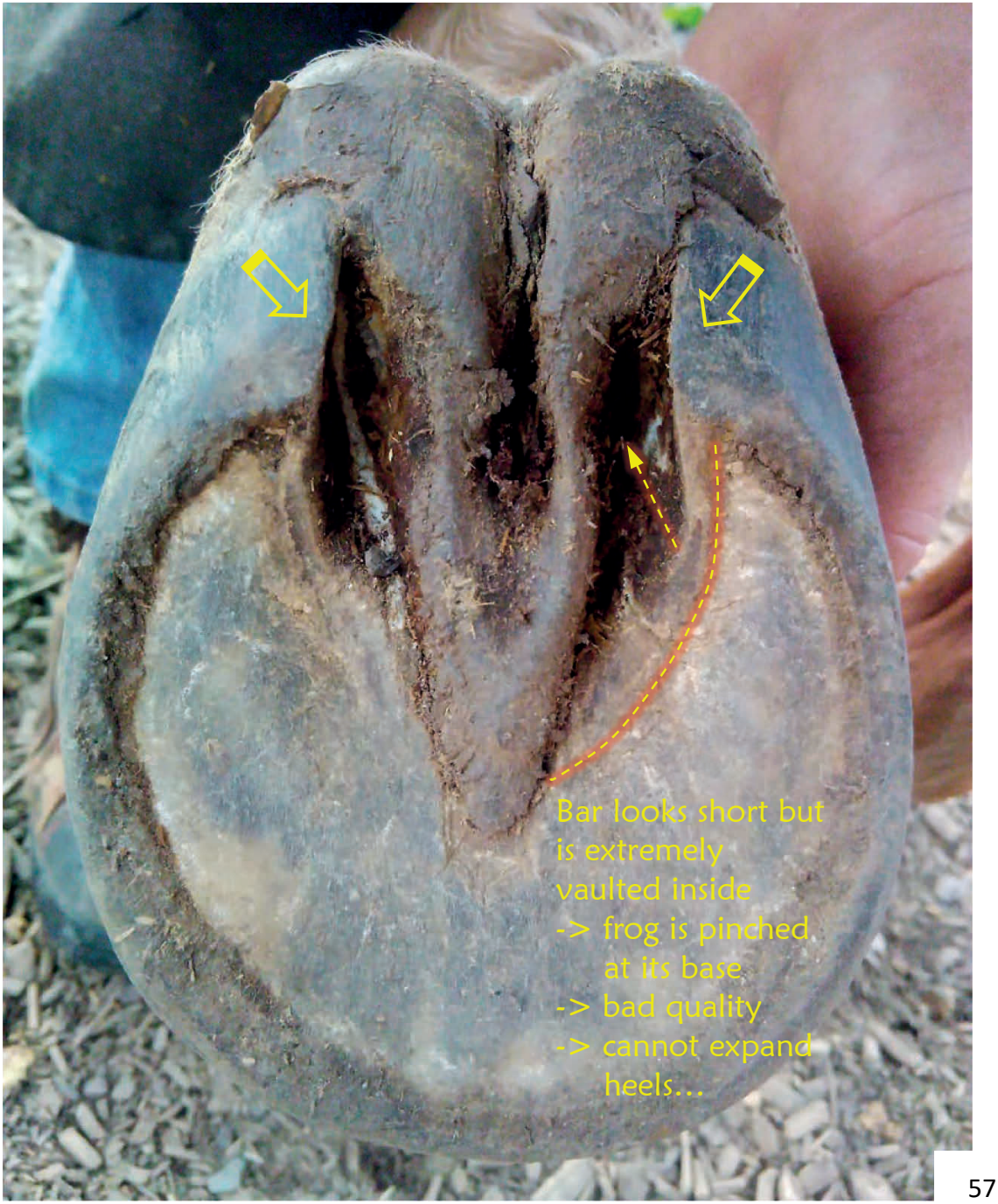
Bar looks short but
is extremely
vaulted inside
-> frog is pinched
at its base
-> bad quality
-> cannot expand
heels...

Open Heel Contraction

- Trim heel walls so that they are not pushed inward by ground force
- Keep toe and breakover as short as possible
- Then walls grow down straight
- Trim bars appropriately as they are levered up inside

- As with bulb contraction, a weightbearing frog is essential, so keep on appropriate ground and address thrush
- It is the responsibility of the horse owner to keep the frog clean
- Tamponades with thrush remedy 2x/week, clean every day and keep the horse on dry ground as much as possible
- Below is indeed the same horse and hoof, 6 months later…

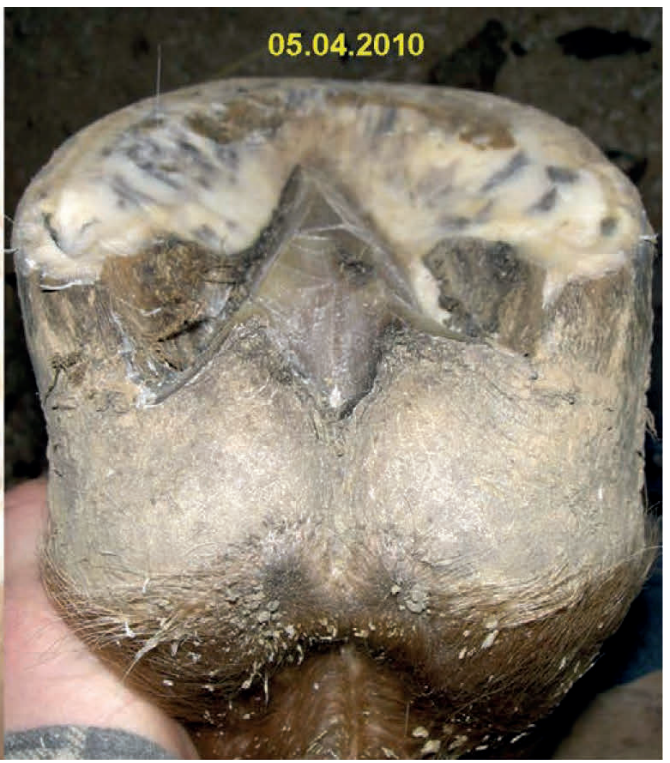

One Sided Heel Contraction

- Here: Diagonal Hoof with toe wide conformation
- Hoof pulls towards outside, medial wall rolls inward -> contraction
- With every step heel pushes further in
- Trim hoof to center line



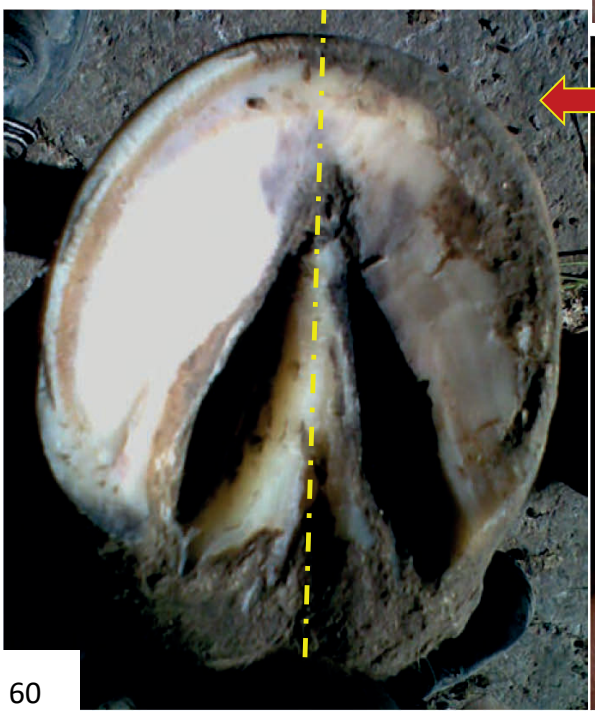


11.11.2007
28.06.2007
Heel contraction

One Sided Heel Contraction

- Bulb has been pushed up and inward over the center line
- Heel is pushed inward upon load

Conformation problems can start with sole contraction. Horse tries to avoid pressure, walks on lateral side wall. This is pushed up and in, one-sided heel contraction develops. Joints adapt to gait, conformation becomes permanent. When cause (sole contraction) is removed, limb becomes straighter and joints readapt with time.

Sole Contraction – Definition and Cause

- Veterinary and farrier literature: description is limited to very severe contraction with claw like hoof appearance
- Starts much earlier and is in fact pretty common in shod hooves, but often unvisible at first glance
- Hoof wants to grow down in conical shape, but shoe keeps width constant. Especially with long shoeing intervals (or fast growth), the dome shaped sole is pushed up. Similar things happen in unshod hooves when old sole does not shed

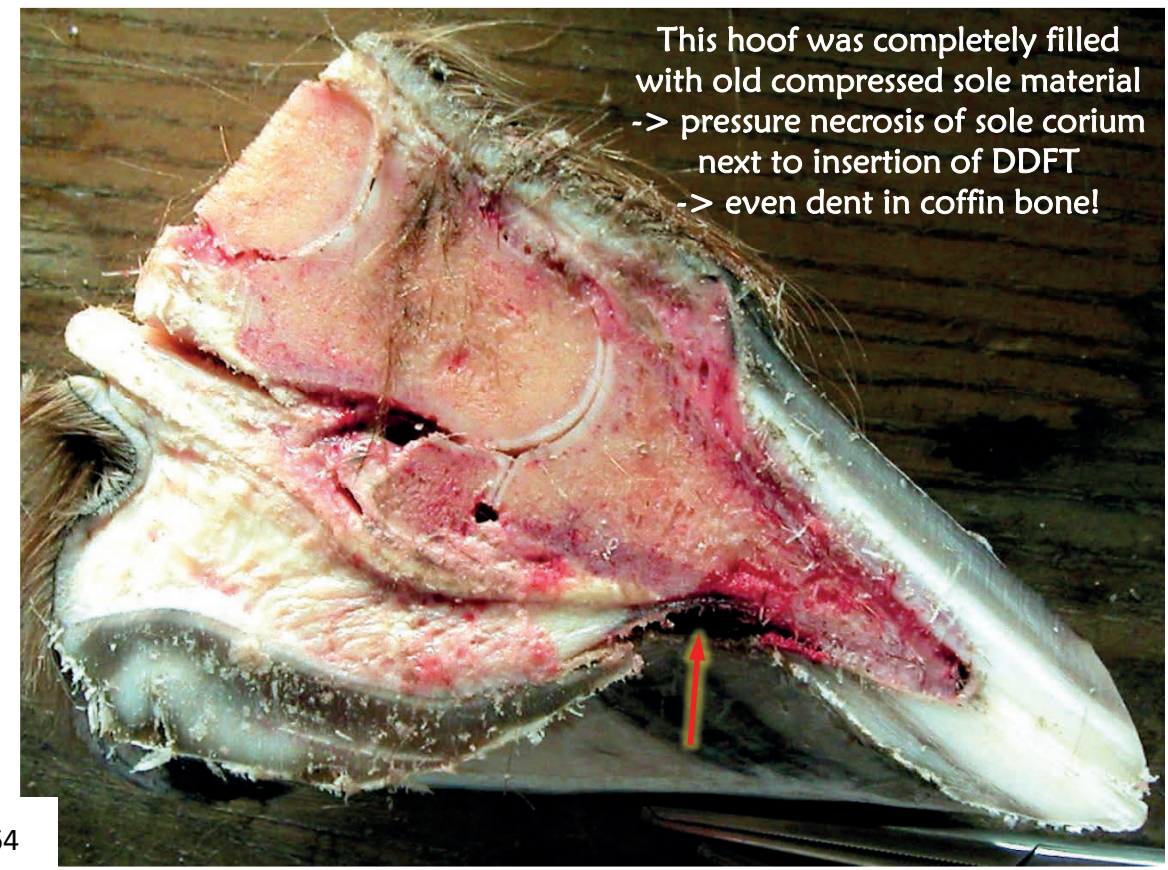

- sole has (inside) a deeper and steeper arch than coffin bone surface
  -> sole exerts pressure around tip of frog
  -> bad horn growth -> sometimes „missing“ frog tips
- Common concavity in coffin bones, respectively healthy hoof sole:
  - +/- 8-10 mm in front hooves
  - +/- 12 mm in hind hooves
- With time, pressure may even deform coffin bone, visible on x-ray:
  - bottom side becomes dented (see green dotted mark below)
  - front side becomes flattened

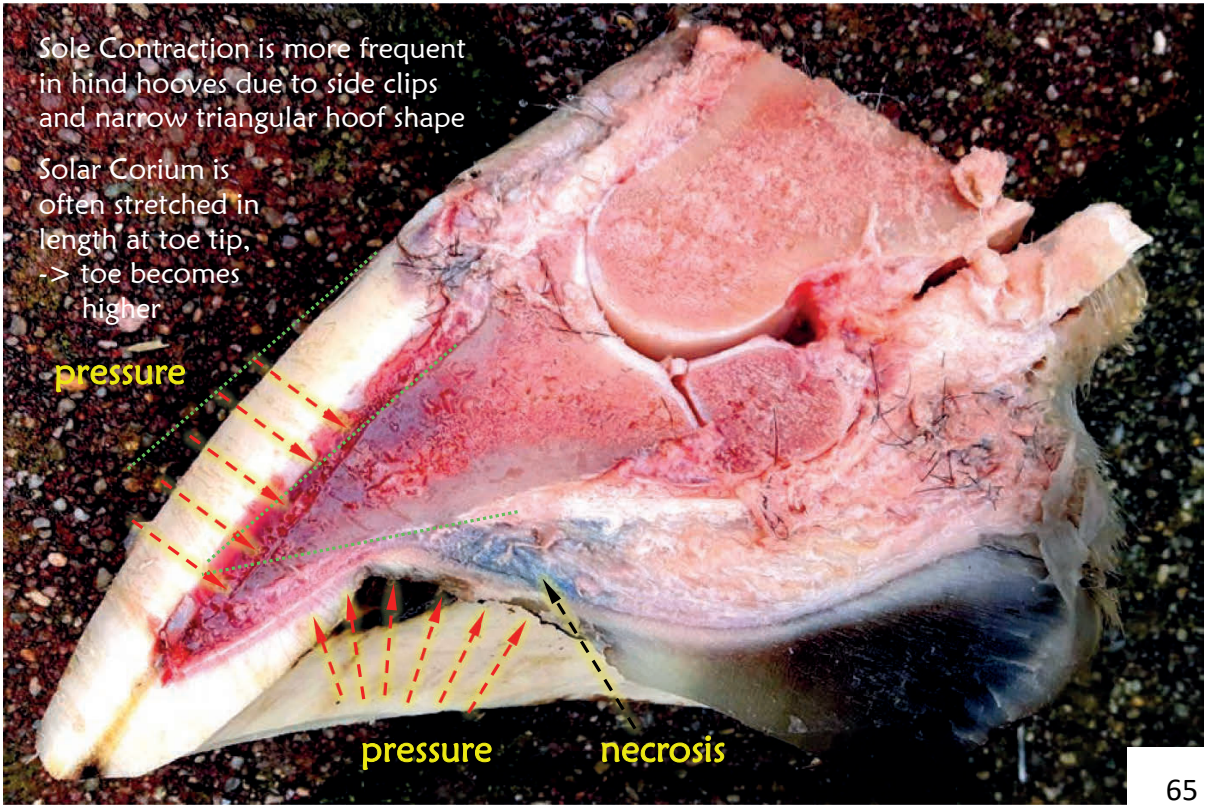

Typical Hoof Shape with severe Sole Contraction



No clips and nails -> sole can return to normal concavity, ususally within 2 weeks

Sole Contraction and Underrun Heels

- Long shoeing intervals of 8 weeks have produced this right hind of a jumping horse
- No lameness, horse apparently sound
- Very high toe, low heels
- Toe angle way too flat
  -> high stress on tendons!

- Horse avoids sole pressure invisibly shifting load to heels
  -> more underrun heels
  -> faster toe growth
  -> gait changes that often remain unnoticed
  -> can lead to tendon issues, muscle dystrophy, spavin…


19.12.2016
30.12.2016


18.01.2017
New growth at ~60° toe angle
Much thicker wall growth though not visible here
Heel more upright, new heel grows even steeper

Sole Contraction and Tip of Frog

- In the same horse, the tip of frog was missing due to the sole contraction causing lack of blood flow causing bad horn
- Sole horn in that area has turned green from pressure
- Sole arch relaxes within ~2 weeks after cause is eliminated
- As sole corium around the frog has suffered from lack of blood - making it insensitive - returning blood flow can cause tenderness even or especially on soft ground

- Complete regrowth of frog tip within 4 weeks
- Visibly relaxed sole arch, back to normal and more upright heels
- Horse is better to ride with higher motivation
- Higher agility in hinds, probably due to better reflexes, that depend on nerve function and proper signals (bulb flexion)
- Read Robert Bowker: „The horse‘s foot as a neurosensory organ“

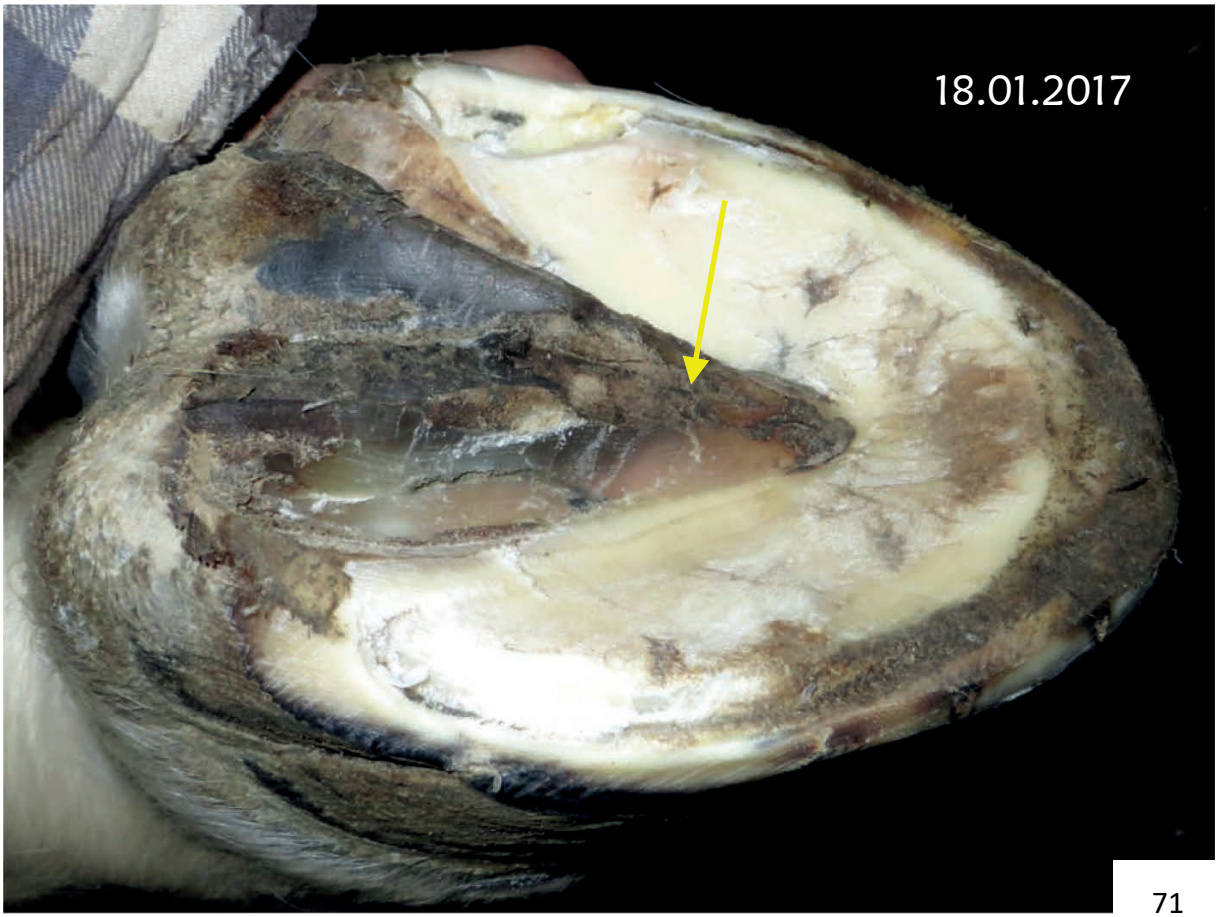

Local Sole Contraction

- Sole shape should resemble a flat cone, not a bowl
- Imagine healthy sole shape starting from the tip of the frog
- Test sole thickness with hoof testers or back of knife blade
- Local contraction happens when sole rim & white line are pushed inwards by stones or hoof nails that act like a wedge in the wall
- Frequent issue in barefoot horses with conformation problems, landing on one side first, pushing stones in the wall
- Or in narrow hooves when farrier nails in wall instead of White Line, so the nail splits the wall and pushes inward



- Sole further inwards gets „stuck“ and cannot grow
  -> area with extremely thin sole
  -> careful: when deformed white line is removed, horse can be lame
  -> remove rim to clear the situation but prepare for glue-on shoe in case horse becomes tender

Coronet Contraction

- Side walls smaller below coronet than at coronet
- Inflammation of side walls, horse lame in turns
- Remove shoes, shorten side walls, load frog (!!!)
  -> side walls at coronet expand upon loading

- Side walls cool in 1 h
- lamefree in 3 days
- 4 weeks later finished 5th at Glock S-dressage event

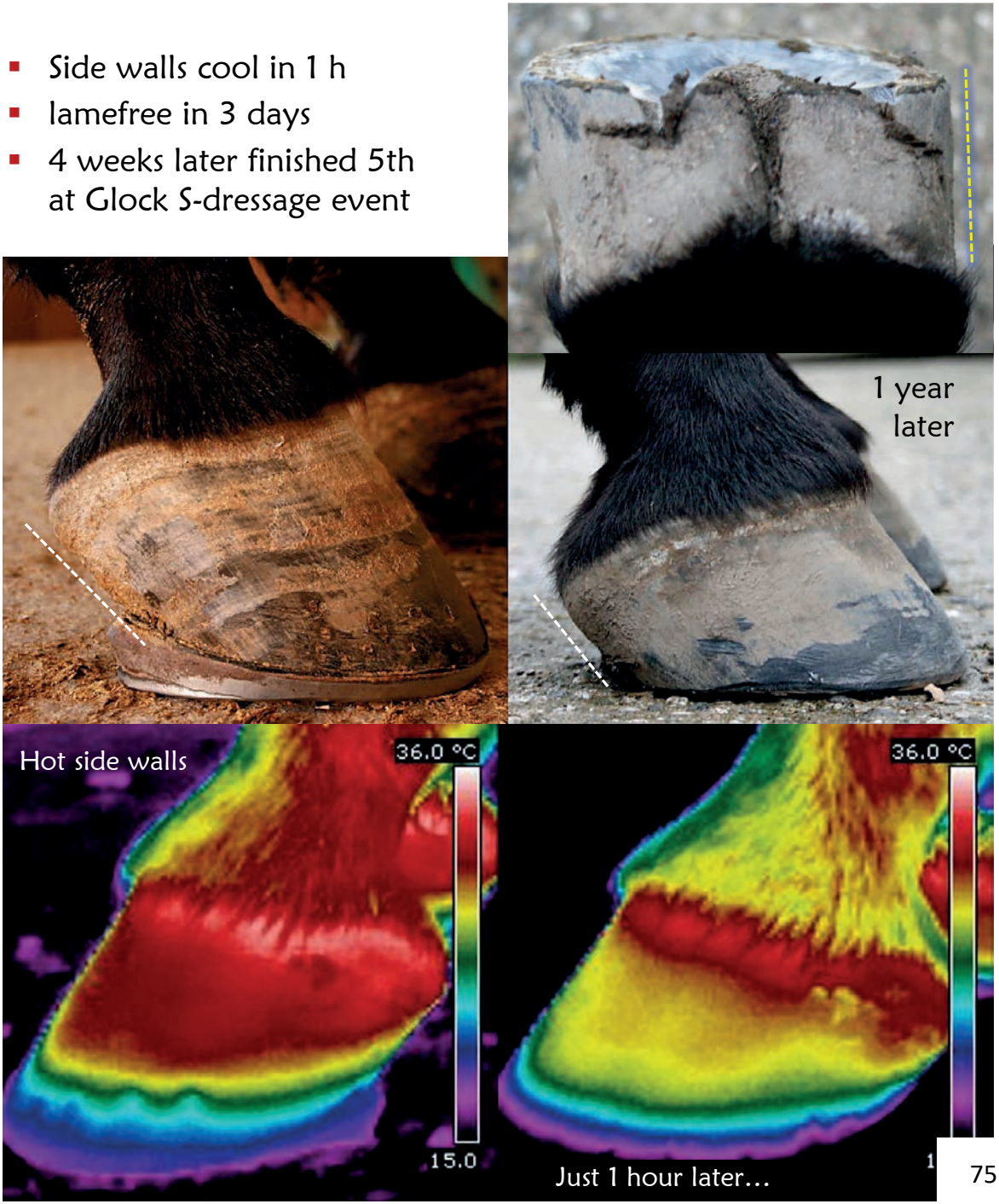

Underrun heels and bar contraction

- Side wall and bar are connected at the heel
- When heels become underrun, or side walls bulge out, the bar will bulge up inside
- Problem is widely unknown in farrier and vet literature
- Bar can cause heel pain and even directly pinch navicular structures

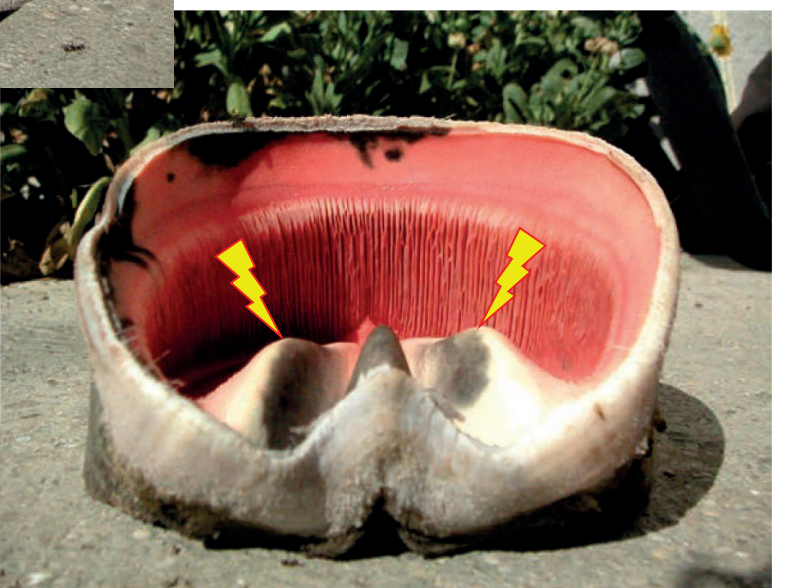

Bar Contraction

- Bar contraction is unknown in farrier and vet literature
- Arch of bar should flatten slighty upon loading
  with bar contraction it does not or even vaults upward
- Common belief: „when the bar is cut short to match sole,
  it cannot pinch“ but that is wrong
- Bars are connected to heels
  -> any deformation of the heels forward/inward
  will push bar forward into the hoof, that is:
  - heel contraction
  - underrun heels
  - direct ground contact of bar
- Bar pressure can cause heel pain
  -> toe first landing
  -> navicular syndrome
- Bar growing forward of hoof center can directly pinch solar
  corium under coffin bone -> very painful
- Bar contraction can push sole arch up and cause sole contraction
- Bar pressure can restrict frog growth
  -> thrush in lateral frog sulcus
- Bar contraction cannot always be seen from outside
- Blood flow is restricted, so nerve function is numbed
  -> horses do not show reaction to hoof testers
  -> problem often remains completely undetected

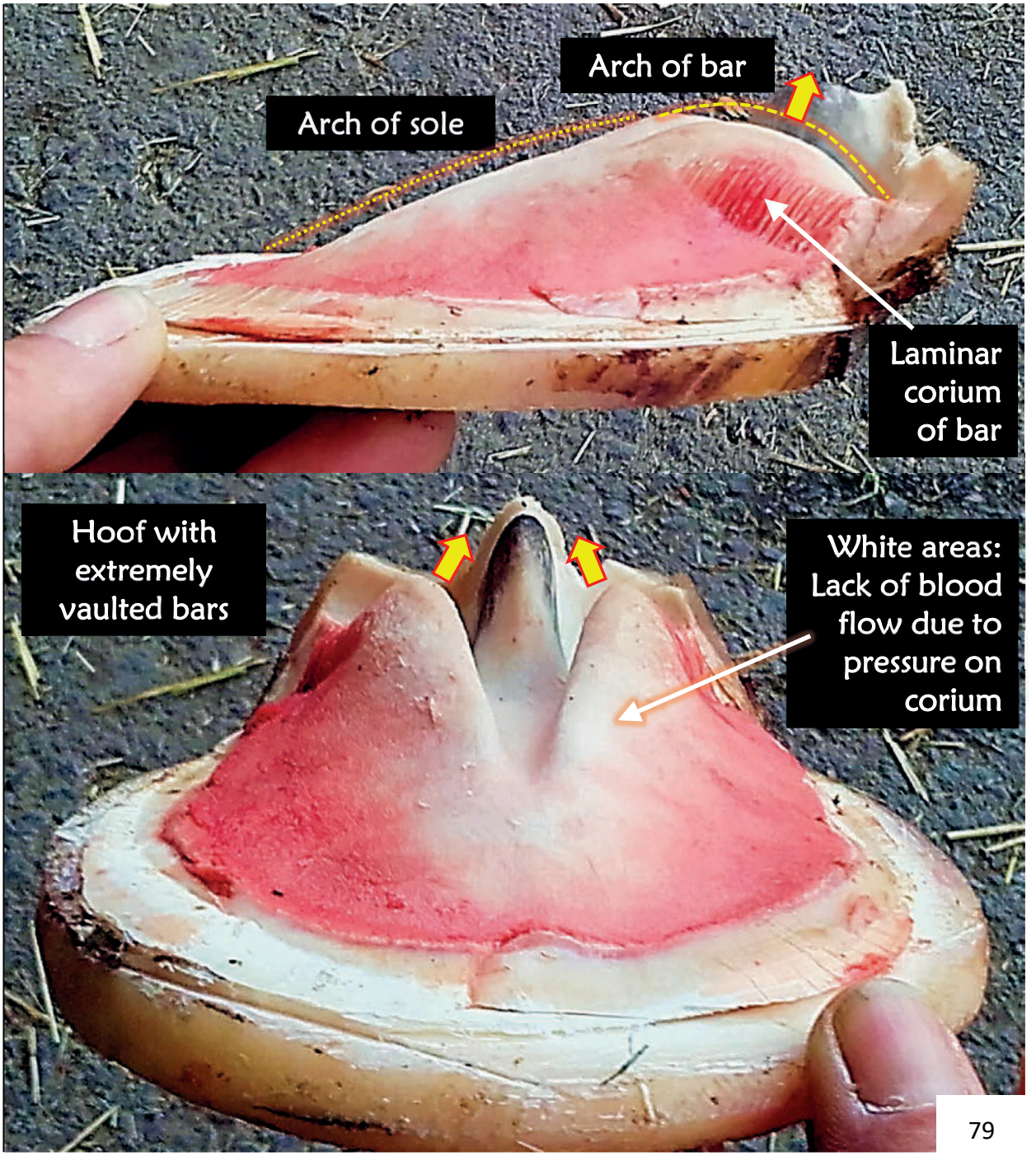
Arch of bar
Arch of sole
Laminar corium of bar
Hoof with extremely vaulted bars
White areas: Lack of blood flow due to pressure on corium

Underrun heels

3 months later

Underrun Heels

- Frequent problem in hinds as horses tend to „stand under“ with pain in front feet or sole contraction or long toes in hinds
  -> heel overloading, slow growth, toe grows faster
  -> regular shoeing periods way too long for these hooves
- negative palmar angle and broken axis, stress on navicular bone
- High pressure on end of coffin bone wings, will disintegrate



- Bars and sole grow flat forward, disguise sole concavity
  -> farrier does not really „see“ how much can be shortened and sole corium may be stretched a bit (see sole contraction) preventing too much shortening with shoeing



Quarter Crack from mechanic wall overload

- Most cracks caused by shear stress between horn tubules
- Wall overload by shoes -> rotation of collateral cartilage -> conflict of front and hind wall tubules
- Side wall either bends out, shears over or when strong enough creates a tearing force at coronet
- Relieve load on side wall -> more load on sole and frog

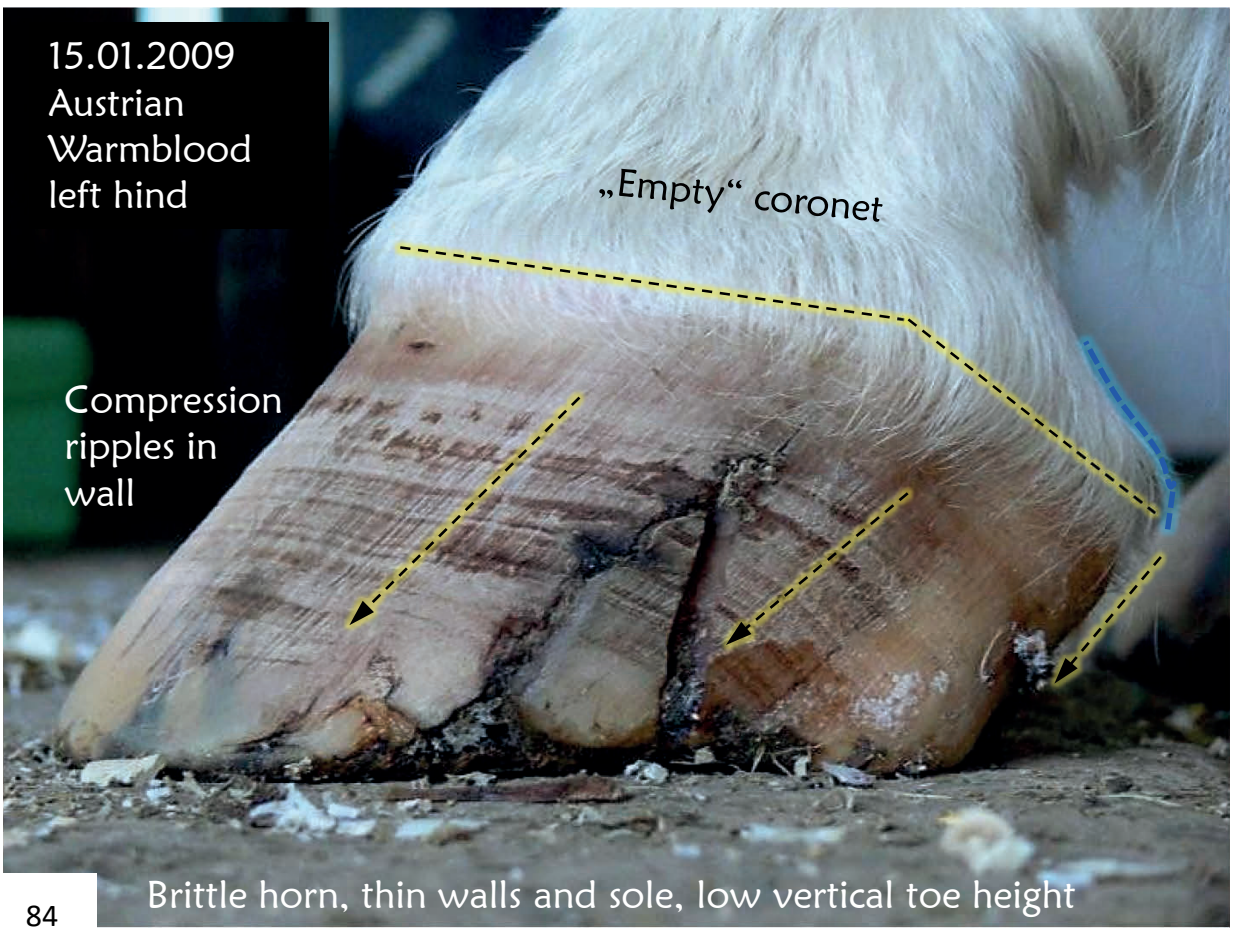

- Coronet will straighten, thicker wall will grow down
- Heel walls will come down to normal position, so collateral cartilage becomes visible at coronet
- „better heel“ -> protection against tendon problems
- collateral cartilage is significantly higher. There is a sling in between that catches the fetlock so it cannot bump to the ground

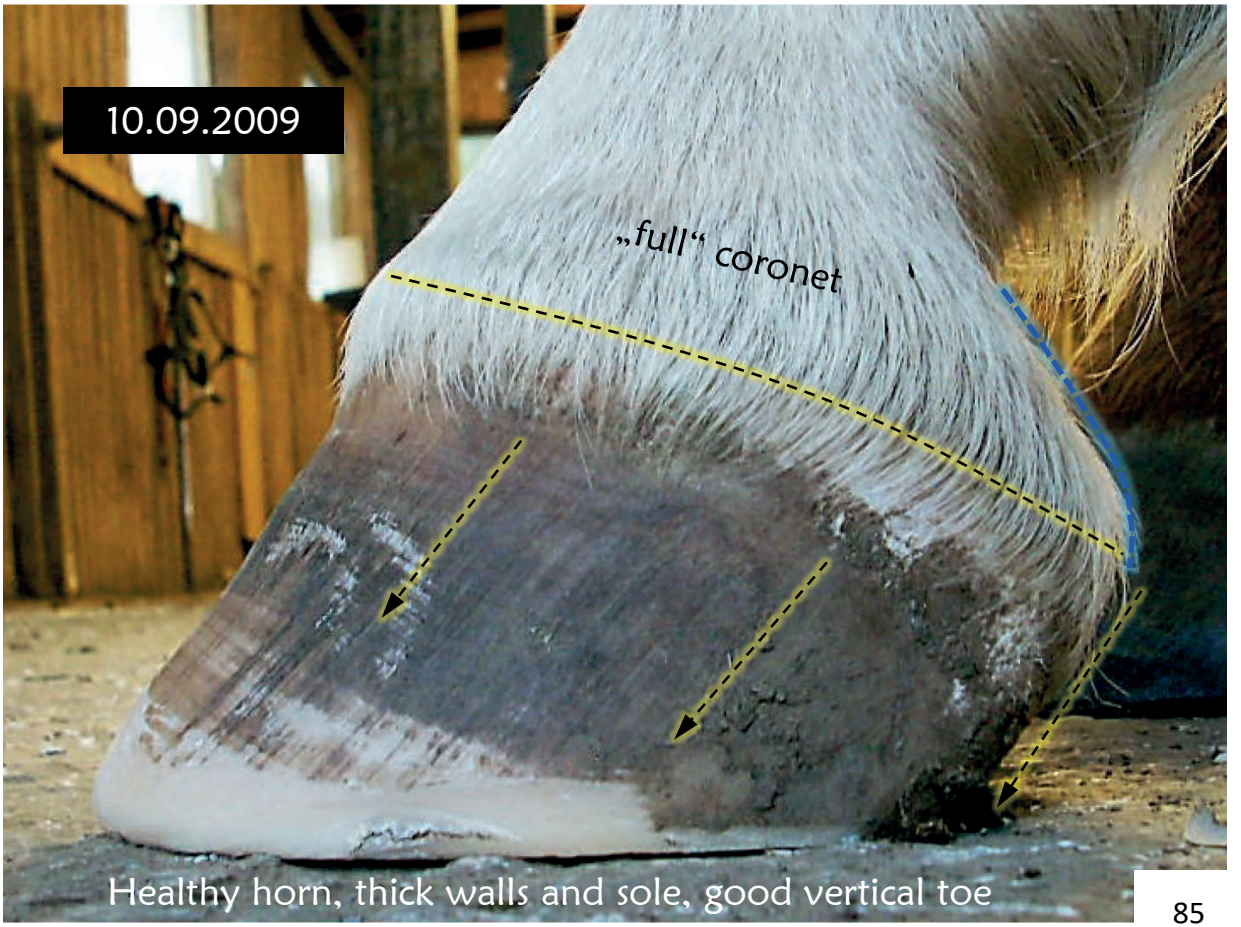

Healthy horn, thick walls and sole, good vertical toe

Quarter Crack from mechanic wall overload

- Shear crack, hind half rotated, tubules growing forward. In front half tubules are growing down along bone
- Hoof cannot relax due to shoe & nails

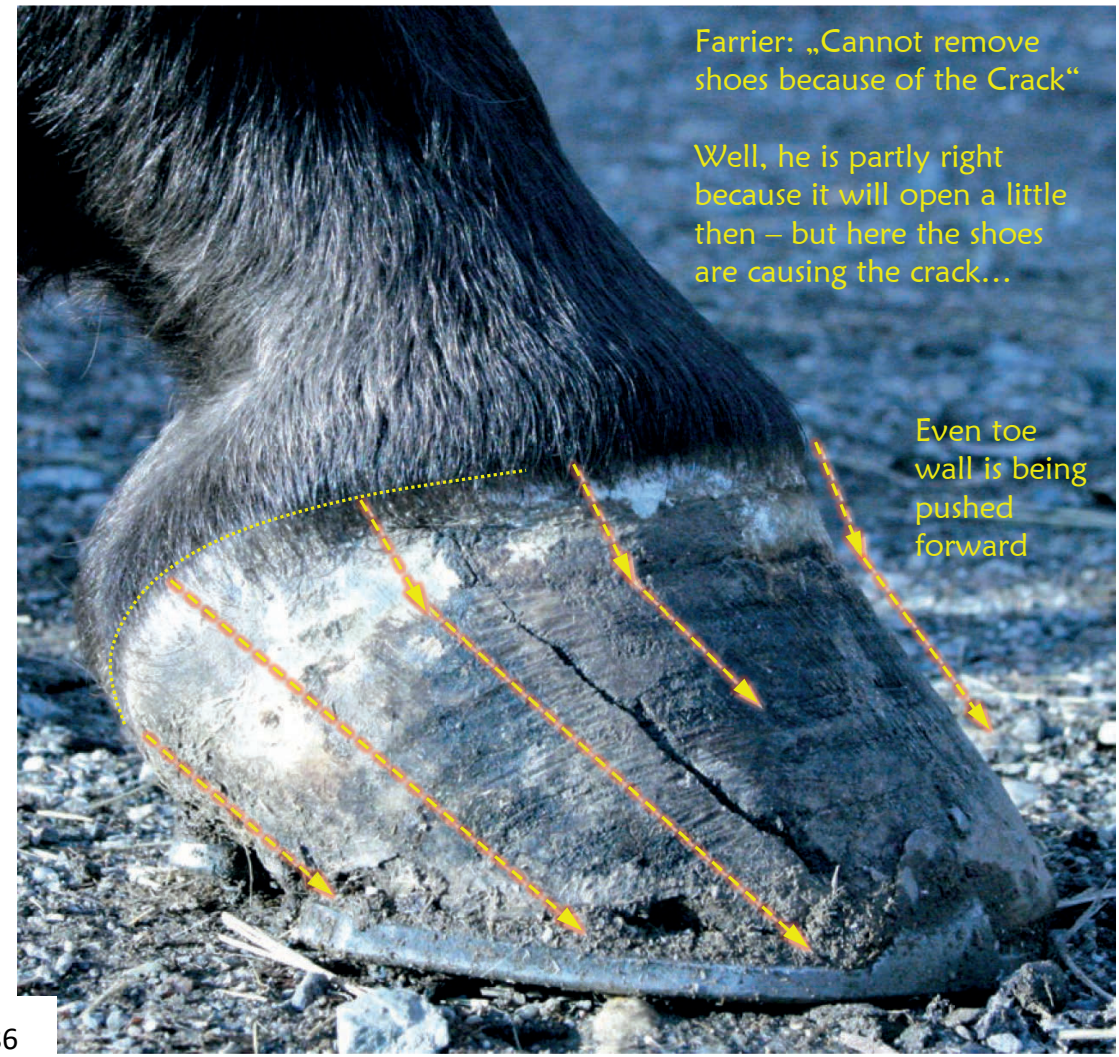

6 weeks

Coronet relaxes

Crack progress stops immediately

Crack will – must - of course open a bit in the bottom as the hind hoof half relaxe. That was no problem.

12 weeks

Coronet relaxed

Straight toe has grown half way down

Crack looks ugly but grows out without causing problems

Quarter Crack from mechanic wall overload

- Diagonal Hoof with toe wide conformation
- Hoof pulls towards outside
- High load on medial side
  -> thin wall
  -> underrun heel
  -> crack

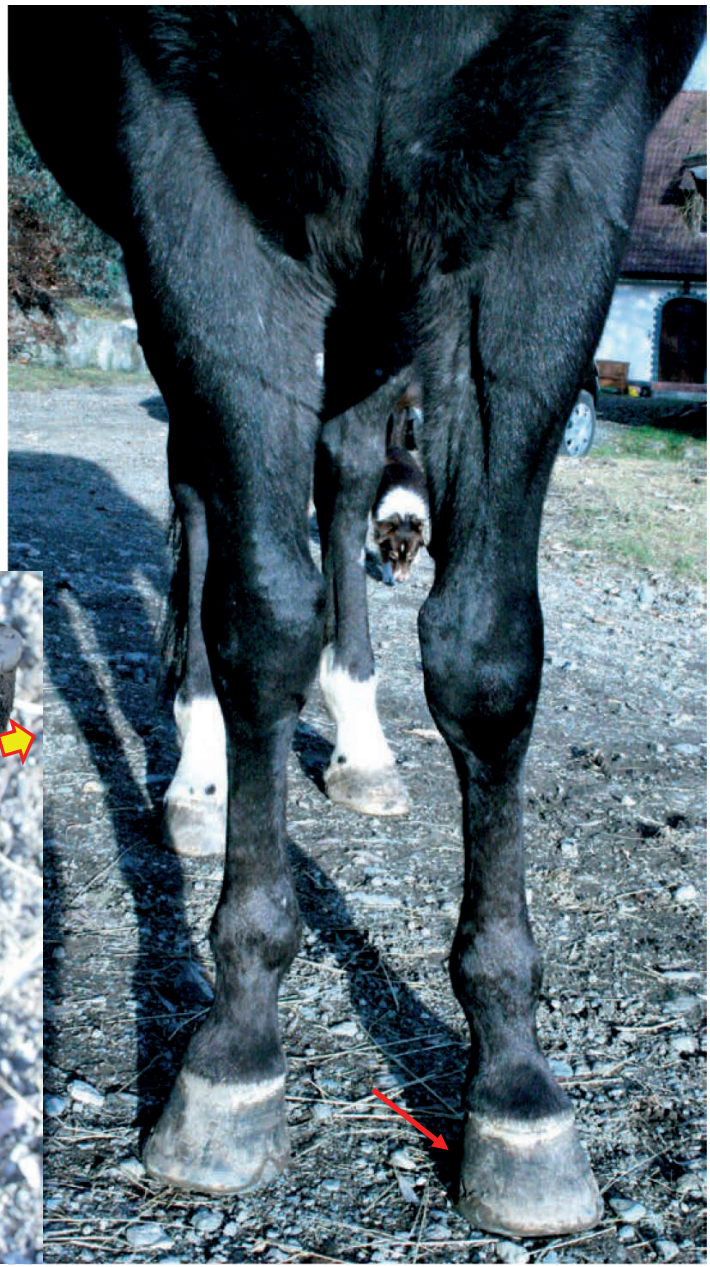

Shoes removed

Lateral wall shortened to restore proper balance

Frog is now weightbearing

6 weeks

Same hoof! Different camera

Coronet and medial wall have relaxed

Bulb height has increased and frog grown much stronger while heels are shorter

Bulbs expanded

Quarter Crack from weak connection

- In this case the laminar connection between coffin bone and front wall was compromized due to nutrition (subclinical laminitis, see red marks due to tearing)
  - nitrate in water
  - short pasture with white clover and buttercups
  - too much alfalfa
  - mineral imbalance

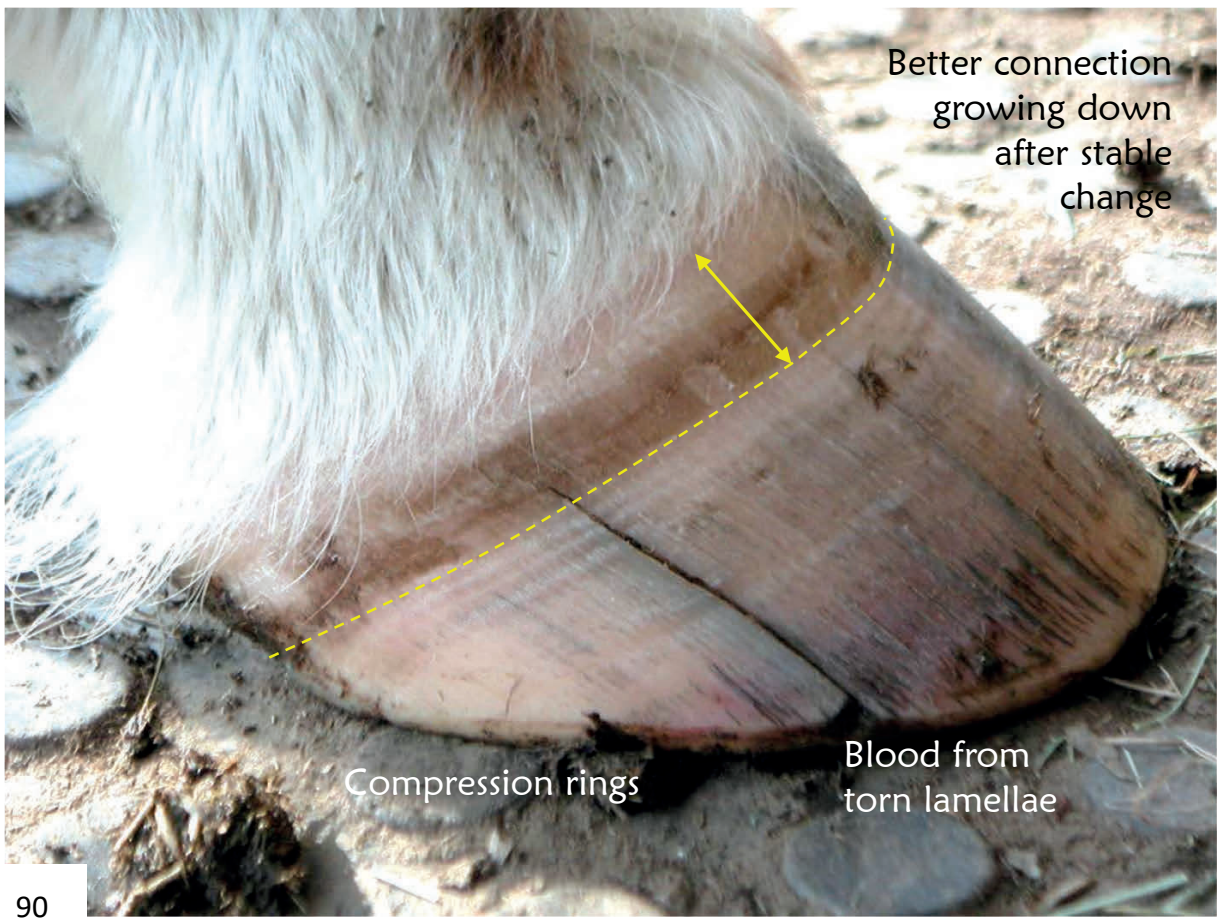

- That will inevitably overload the side walls
  -> side walls become flatter, heels underrun
  -> shear stress produces crack in upper hard layer
- No mechanical overload, horse was unshod, walls short
- Cause needs to be addressed!
- Here: stable change. New hoof grew down perfectly

Local Contraction

- In this case the bulb corium was pinched in between a wedge of frog horn in the central sulcus and the heels. No frog canker.
- Bulb horn cannot grow due to lack of blood supply
- Bad horn quality is eaten away by bacteria, corium bulges out

Analyze the situation: why is it not growing
Do not immediately cut the obvious (corium!)

Remove frog horn wedge in sulcus as deep as possible to reduce the pressure

Trim horn in frog sulcus frequently so corium can return to normal -> permanently fixed

3 weeks later healthy bulb horn has regrown

Wrong way…

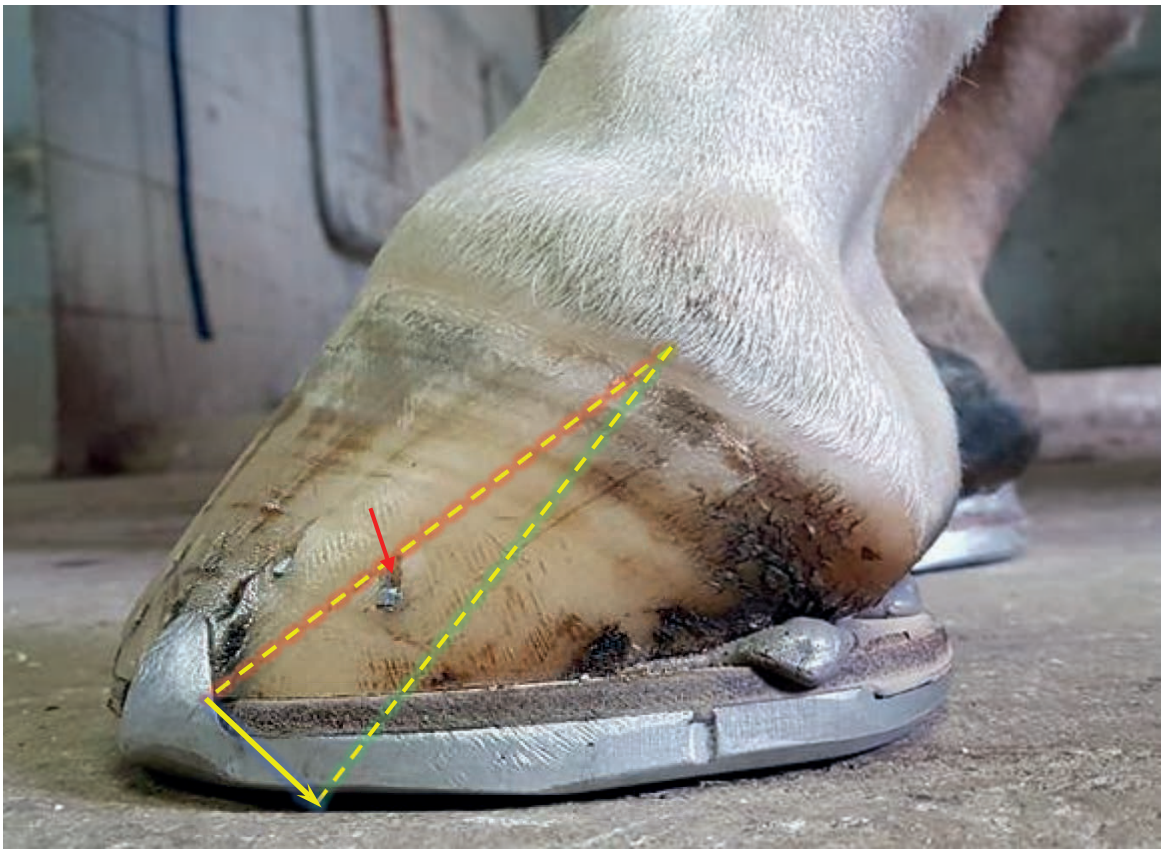

- Impression material under frog is basically a good idea to unload heels and side walls, but a closed bar shoe will prevent „active loading“
- Hoof nails are fixing the flat side wall tubules in their position
  Shoe prevents gradual & constant shortening of side walls by abrasion
  -> side walls cannot relax or grow much steeper.
- Hoof angle still too flat, imagine toe length in 6 weeks
- ---> no improvement of hoof capsule deformation

- Intention of Banana Shoes: improve biomechanics
- Problem: steel shoe is flexible under horse weight
  -> very high pressure on side walls pushes coronet up
  -> hoof cannot stretch in length, horn tubules flat on shoe
- frog gets less ground support
- ---> no improvement of hoof capsule deformation

Navicular Syndrome

- Unphysiological movement e.g. due to heel pain or otherwise uncomfortable hoof (also tenderness!)
  -> Horse overloads navicular area
- Or coffin bone too flat -> high stress on navicular
- Several structures can be harmed
  -> inflammation of impar ligament
  -> trauma to navicular bone by high pressure of deep digital flexor tendon (DDFT)
  -> inflammation of navicular bursa by high pressure
  -> inflammation of insert point of DDFT
  -> inflammation of lateral ligaments to fetlock…
- Manifold possible causes, mostly hoof deformation:
  - Underrun heels
  - heel and bulb contraction
  - bar contraction
  - sole contraction
  - thrush
  - flat hooves with thin sole or sensitive frog
  - subclinical laminitis…
- When hooves are brought back to comfortable shape and horse returns to a physiologic gait, most navicular syndromes disappear, even in many cases that are verified by MRT


Now you already see it by yourself - this hoof is in severe trouble...
5 year old paint horse stallion should be put down due to „incurable“ navicular
lame free immediately after hoof correction

Laminitis - Chronic Founder

- Laminitis is inflammation of laminar corium
- Immediate veterinary intervention necessary!
- Main causes:
  - high insulin (overfed ponies and certain breeds)
  - high cortisone (by vet application or cushings)
  - short grass (high sugar, Ergovaline poisoning)
  - poisonous plants (white clover, buttercups…)
  - nitrate in water
- Loss of laminar connection -> chronic founder
- Loss of main weight bearing structure! That is a worst-case scenario for a horse. Do everything that this never happens
- Subliminal or low grade laminitis can cause chronically foundered hooves without ever having visible acute laminitis
- coffin bone either sinks down in hoof capsule or rotates, depending on hoof balance
  -> overload of sole
  -> flat and often thin sole, loss of sole concavity
  -> hoof walls are pushing into coronet
  -> overload of side walls
  -> flat side wall tubules and underrun heels
  -> dished and rippled wall growth
- Keep walls short, cushion frog and sole, apply hoof protection!
- Boots with pads or glue-on shoes are good solutions
- reestablish hoof balance, no pressure under tip of coffin bone
- hooves have to be corrected in short intervals as heels grow faster at the beginning and long walls will overload again

Extreme example of cresty neck found in Italy. Fat pads can be sign of EMS (Equine Metabolic Syndrome) that makes horses prone to founder when being overfed

Chronic founder hoof with dished toe wall and very fast heel growth.

Imagine a healthy hoof from the coronet down to get a rough idea about coffin bone rotation. X-ray is necessary for verification though.

Hooves with thick walls compared to horse weight (e.g. donkeys, mini ponies, Lippizan horses) sometimes do not show founder ridges

White Line Deformation

- White Line is sealing material between wall (laminar layer) and sole
- Not the bright white rim of the unpigmented wall but rather yellowish, opaque softer horn (light can shine through)
- Wall grows 1 cm/month but sole only 3-4 mm, without elastic sealant the gap would rip open. Needs to be tight against bacteria
- White Line is often eaten away by fungus and bacteria
  -> when it is dirty, it might seem to be widened but further below it is fully ok
- When laminitis has triggered coffin bone rotation or sinking, that is the lamella connection is torn and stretched, the white line will widen. This is not visible immediately, but after about 6-8 weeks

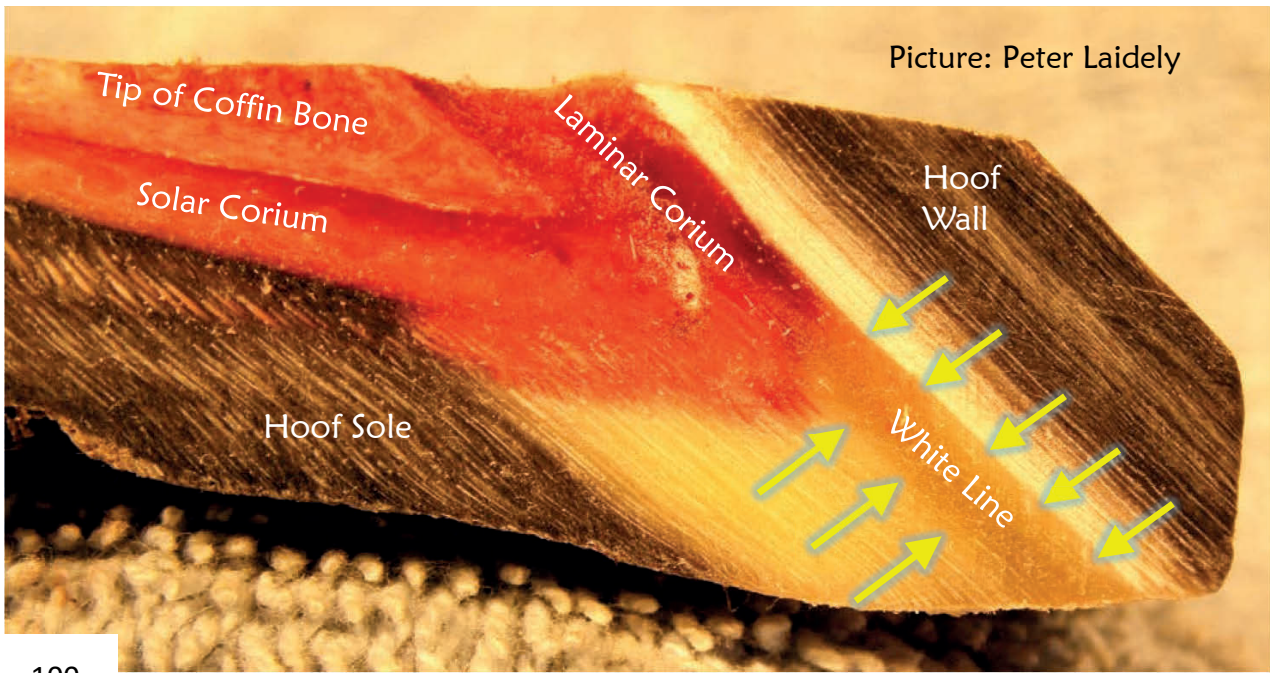

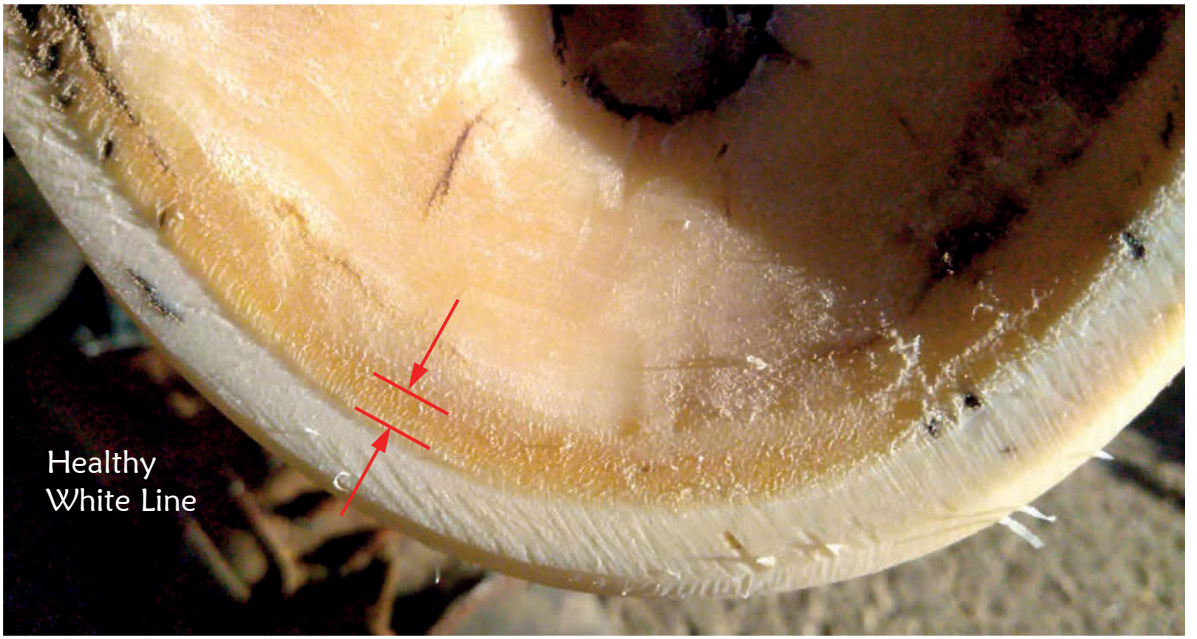
Healthy
White Line


Stretched bloody
lamella after acute
laminitis with coffin
bone rotation

Founder from inside

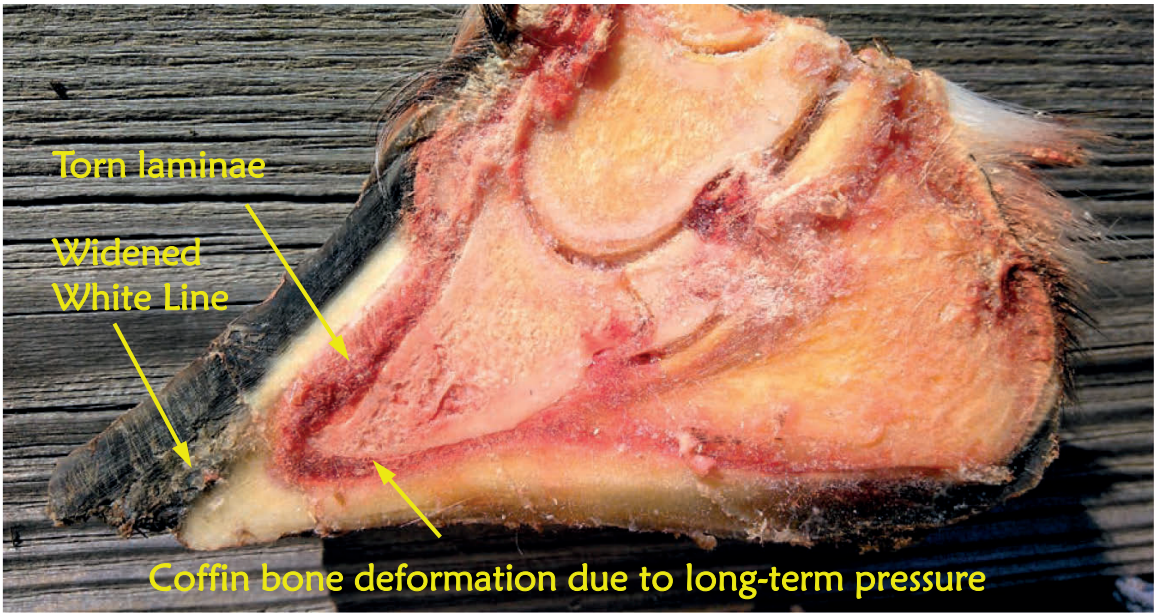


New hoof wall
starting to grow in
right direction
Lost
connection
White Line still seems narrow at ground level


Founder
ridges

Weak Laminar Connection



- This is a ex-shod thoroughbred with nitrate in drinking water
- Mechanic compression rings in wall
- steeper shoulder below coronet, „empty“ coronet
- Collateral cartilage visibly low in capsule
  - -> coffin bone still parallel to wall but too much load on coronet and sole -> thin sole, slow wall growth
  - -> no acute laminitis or founder but similar hoof situation
  - -> sometimes caused by lack of B-vitamins due to guts or stomach problems (vitamin B6 and B12)

Subclinical Founder / Slight Sinking

- This is a metabolic haflinger on short grass pasture with „feed rings“
- Mechanic compression rings in wall, parallel to coronet
  -> no coffin bone rotation
- steeper shoulder below coronet, „empty“ coronet
- Thin hoof sole and very sensitive on gravel
  -> weak laminar connection with slight sinking of coffin bone
- problem hardly visible on x-ray

Founder - Coffin Bone Rotation

- Loss of laminar connection especially at toe
- Heels grow faster, toe horn compressed -> wedge shaped ridges
- Reestablish hoof balance (here shorten the faster growing heels) Correct balance is key factor for rehabilitation
- Better healthier hoof growing down from the top. New hoof within about 1 year – if cause is reliably removed (nutrition!)

Sinker – Dropped Coffin Bone

- Complete loss of laminar connection, hollow all around coronet, collateral cartilage has disappeared into heels (blue arrow)
- Here: laminitis caused by cortisone injection in a sports horse
- Regular shoes without sole support were left on for 2 months -> forced walls up & pinched circumferential artery -> high pain
- When circumferential artery is pinched -> no sole growth and danger of coffin bone infection. Very high mortality.

Foundered Haflinger, loose hoof capsule

Heels trimmed -> coffin bone ground parallel

- Laminitis caused by severe overfeeding (first mountain pasture, then fruit orchard and neighbor owns a bakery…)
- Hoof capsules in both hind hooves completely loose and rotated
- No hoof sole horn any more, solar corium completely exposed
  -> mild desinfection, establish ground parallel coffin bone, wrap in diapers, protective hoof boots and soft pads

Started to remove toe lever

- There is hope:
  Sole starts growing immediately.
  already good amount of (soft) sole in 1 week
- No pressure on coronet -> wall comes down fast and straight
- New hoof capsule grew down within 7 months



Arnold Böcklin, Centaur at a Village Blacksmith Shop, 1888
Budapest Museum of Fine Arts, Budapest, Hungary